

Comparison of Automatic and Manual Prescription Protocols for Brain 3D MRSI

E. Ozhinsky^{1,2}, D. B. Vigneron^{1,3}, S. M. Chang⁴, and S. J. Nelson^{1,3}

¹Surbeck Laboratory of Advanced Imaging, Department of Radiology and Biomedical Imaging, University of California, San Francisco, San Francisco, CA, United States, ²UCSF/UCB Joint Graduate Group in Bioengineering, University of California, San Francisco, San Francisco, CA, United States, ³Department of Bioengineering and Therapeutic Sciences, University of California, San Francisco, San Francisco, CA, United States, ⁴Department of Neurological Surgery, University of California, San Francisco, San Francisco, CA, United States

Introduction: Magnetic Resonance Spectroscopic Imaging (MRSI) is an important tool for diagnosis and evaluation of brain tumors. Manual prescription of brain 3D MRSI is often difficult, since the selected volume (PRESS box) needs to cover the tumor as well as other potential areas of interest, while avoiding subcutaneous lipids and sinuses. Outer-volume suppression (OVS) with sat bands is used to suppress signal from those areas, however manual placement of sat bands requires operator training. Overall, the difficulty in prescribing 3D MRSI has limited the brain coverage obtained, introduced variability in the acquired data and hindered adoption of spectroscopy in a clinical setting. We have developed a number of techniques to simplify prescription of MRSI exams, such as octagonal selection (1), automatic sat band placement (2) and oblique PRESS box placement (3). Other interesting approaches to automatic sat band placement were developed by Hovdebo et al.(4) and Li et al.(5) The goal of this work was to evaluate the coverage and data quality of MRSI protocols with manual and automatic prescription in order to determine the most effective strategy for implementing automatically prescribed spectroscopy for routine scans of patients with brain tumors.

Methods: MRSI data were acquired using a commercially available 8 channel head coil (isotropic nominal voxel size: 10 mm, TE = 144 ms, TR = 1100-1500 ms) with an EPSI flyback sequence. Raw data were processed offline using software developed in our laboratory (6). The following acquisition protocols were tested:

1. **Standard Lactate-edited MRSI:** 6 fixed sat bands at the edges of the PRESS box, 6 manually placed sat bands. (16x16x16 field of view, acquisition time $T_{acq} = 9$ min)
2. **Lactate-edited MRSI with octagonal selection:** Octagonal selection with cosine-modulated saturation pulses was applied instead of fixed sat bands (1).
3. **Automatic sat band placement:** 6 fixed sat bands and 9 sat bands automatically prescribed from a T1 Fast SPGR image (2) were applied. (18x18x16, $T_{acq} = 8$ min)
4. **Automatic sat band placement with octagonal selection**
5. **Same as protocol 4 with spectro-spatial RF excitation pulses** to eliminate J-modulation of the lactate signal (7).
6. **Automatically prescribed oblique lactate-edited MRSI:** PRESS box size, position, oblique angle and sat band placement were optimized from a T1-weighted SPGR image to maximize coverage while approximating the shape of the skull (4). Generated parameters were loaded into an MRSI pulse sequence. ($T_{acq} = 12$ min.)

To determine the volume covered, masks of PRESS volume and sat bands were generated from prescription parameters. The volume covered was calculated as the number of 1cc voxels within the PRESS volume not overlapping with the sat bands more than 50%. To quantify the quality of data and the amount of lipid contamination, the SNR of Choline, Creatine, NAA and Lipid peaks were calculated within the healthy brain tissue (defined by a white-matter mask). SNR efficiency was calculated by dividing SNR values by square root of T_{acq} .

Results: We have collected MRSI data from 3 healthy volunteers and 37 patients with brain tumors so far, usually acquiring two sets of MRSI data per exam using different protocols. The total number of datasets for each protocol were $N_1 = 12$, $N_2 = 14$, $N_3 = 10$, $N_4 = 16$, $N_5 = 9$, $N_6 = 5$. Fig. 1 (a,b) shows examples of a manual prescription (protocol 1) of PRESS box (red) and sat bands (orange) together with fixed sat bands (gray). Fig. 1 (c,d) shows automatically placed sat bands (protocol 4, orange) and cosine-modulated bands for octagonal selection (gray). Fig. 2 shows axial and sagittal slices from an MRSI dataset with automatic oblique prescription (protocol 6). Fig. 3 shows average coverage and SNR efficiency for lipid and NAA peaks for the protocols described above (the protocol number is in parentheses). Automatic oblique prescription allowed approximately 3x increase in coverage volume, compared to the standard protocol. The NAA signal shows no decline in data quality in datasets with bigger coverage. We did not detect a significant increase in lipid contamination.

Discussion: Our data showed that automatic placement of sat bands not only saved time during prescription, but also allowed to cover a larger volume in the brain. This is especially useful when imaging tumors located near the edge of the brain and multi-focal tumors. We found that it was hard to obtain data from the inferior portions of the brain when acquiring data axially due to the field inhomogeneities and lipid contamination caused by sinuses and orbits. Oblique acquisition helped solve this problem.

The use of an automatic oblique PRESS box placement should allow the set up for MRSI acquisitions to become routine. In the future, we are planning to implement the automatic prescription protocols for all brain tumor scans at our institution.

References and Acknowledgements: [1] Osorio JA et al. (2009). Magn Reson Med, 61(3), 533-. [2] Ozhinsky E et al. Proc. 17th ISMRM, 2009: 1580. [3] Ozhinsky E, et al. Proc. 16th ISMRM, 2008: 2377. [4] Hovdebo JL et al. Proc. 17th ISMRM, 2009: 2376. [5] Li T et al. Proc. 14th ISMRM, 2006: 3086. [6] Nelson SJ. (2001). Magn Reson Med, 46(2), 228-. [7] Cunningham, CH et al. (2005). Magn Reson Med, 53(5), 1033-.

We would like to thank Adam Elkhaled, Wei Bian, Trey Jalbert and Chris Williams for help with data acquisition and processing. This research was funded by UC Discovery grant ITL-BIO04-10148 in conjunction with GE Healthcare.

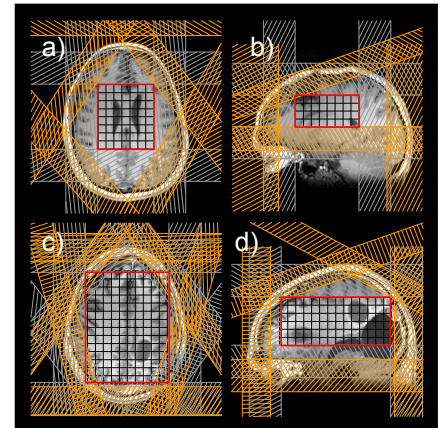


Fig. 1 MRSI prescription with (a,b) manually and (c,d) automatically placed sat bands

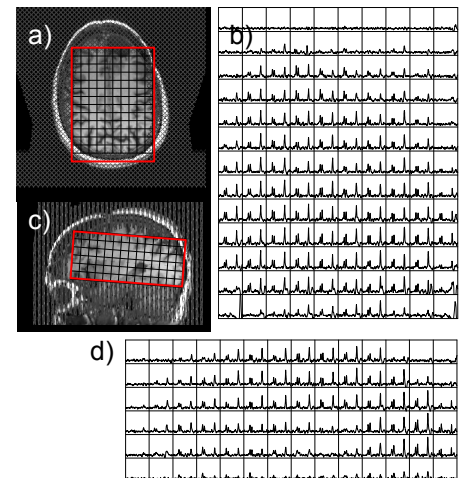


Fig. 2: Automatically prescribed 3D MRSI exam: (a,b) - axial-oblique slice, (c,d) - sagittal slice.

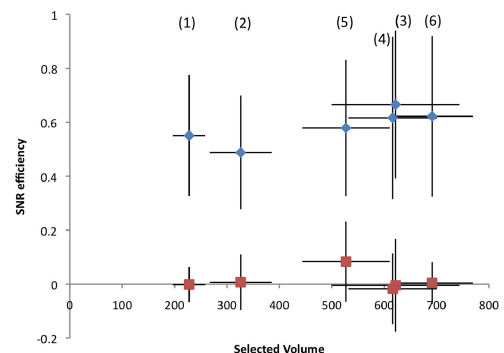


Fig. 3: NAA and lipid SNR efficiency vs. mean brain coverage volume (cm^3); error bars: ± 1 std. dev.