

Histopathological Composition of Prostate Tissues and Their Impact on DCE MRI Measures

S. M. Noworolski^{1,2}, K. Kuchinsky³, M. Nyström¹, J. Kurhanewicz^{1,2}, D. B. Vigneron^{1,2}, P. R. Carroll⁴, K. Greene⁴, and J. Simko³

¹Radiology and Biomedical Imaging, University of California, San Francisco, CA, United States, ²The Graduate Group in Bioengineering, University of California, San Francisco and Berkeley, CA, United States, ³Pathology, University of California, San Francisco, CA, United States, ⁴Urology, University of California, San Francisco, CA, United States

Introduction

Prostate cancer may present with mixtures of benign and cancerous tissues of varying degrees and types, as well as in multiple locations throughout the gland. This variability makes it difficult to establish MR patterns in different tissue types. The purpose of this study was to: 1) assess the presence of different tissue types within the prostate and within cancerous regions of interest (ROIs), and 2) gauge the impact of these measures on DCE MRI peak enhancement (PE) and slope in comparison to healthy tissues and in Gleason Grade 3+3 cancers versus 4+4 cancers.

Methods

Fourteen men with untreated prostate cancer received 3T MR exams prior to undergoing prostatectomy. DCE MRI was performed with a series of 3D FSPGR images (TR/TE/flip=5/2.1ms/6°, 2.7mm slices, matrix=192x128, 50 timepoints, bolus injection of 0.1mmol/Kg Gd-DTPA). The subjects' excised prostates were then entirely embedded in paraffin using either whole mounts (n=12) or quarter sections (n=2) for histologic review. Cancerous regions were delineated, estimating the % of each Gleason Grade, % of stroma, and % benign glandular tissue. Inflammation, mucin, high grade prostatic intraepithelial neoplasia (HGPIN) and atrophic areas were identified throughout each gland. The presence and percentages of tissue types were assessed in patients, cancerous ROIs, and cancerous lesions and compared for Gleason Grade 3+3 versus ≥ 4+4 cancers.

In 9 patients with cancerous lesions > 0.5cc, ROIs were manually drawn in cancerous regions and normal peripheral zone regions on T2-weighted images of the prostate based on visual alignment to the digitized histopathology slides, adjusting as necessary to stay within a clear tissue type by imaging, due to tissue distortions between histology and imaging. DCE MRI data were aligned to the T2-weighted images and values for PE and slope at the corresponding ROI locations were calculated. Results for cancerous tissues were normalized to normal peripheral zone values for each subject. Values were then normalized to the concentration of cancer in the ROI. PE and slope were compared between Gleason Grade 3+3 and 4+4 cancers before and after concentration normalization using t-tests.

Results

Regions of cancer greater than a few mm in size were found in 11/14 subjects by histopathology; 2 others had only a very small region of cancer on one slide while one had no cancer detected in any prostatectomy sections. In total, 106 distinct cancer ROIs were delineated over 36 lesions, yielding an average of 3 lesions per patient. The breakdown of tissue types in the patients and cancerous lesions are given in Table 1, and in cancerous ROIs in Table 2.

Table 1 – Presence of Tissue Types (>0.1 cc) Within Subjects and Within Cancerous Lesions

Tissue Type	Gr 3+3	Gr 3+4	Gr 4+3	Gr 4+4	Gr 3+4+5	Stroma	Cystic atrophy	Inflam.	HGPIN
# Subjects (%) [n=14]	2 (14%)	4 (29%)	2 (14%)	2 (14%)	1 (7%)	13 (91%)	14 (100%)	9 (82%)	5 (36%)
# Cancer Lesions (%) [n=36]	27(73%)	0	2 (7%)	6 (17%)	1 (3%)	28 (93%)	0	4 (13%)	1 (3%)

Table 2 – Presence and Percentage of Tissue Types Within Cancerous ROIs

Cancer ROIs	Benign Glandular	Stroma	Gr 2	Gr 3	Gr 4	Gr 5	Cancer 2-5	Mixtures of Grades	Inflam	Mucin	HGPIN
106	43 (41%)	102 (96%)	0	85 (80%)	21 (20%)	2 (2%)	106 (100%)	2 (2%)	8 (8%)	1 (1%)	1 (1%)
Avg%ROI	14%	32%	0%	57%	81%	90%	64%				

Grade 3+3 Grade ≥4+4

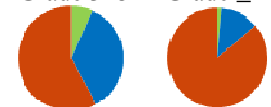


Figure 1 - Tissue Types in Cancer ROIs: red=cancer, blue=stroma, green= benign glandular

On average, cancer ROIs had only 64% cancer and included 6% benign glandular tissue and 31% stroma. In particular, higher grade lesions (≥4+4) had significantly higher percentages of cancer than the 3+3 lesions (87% vs. 58%, p<0.00001) (Figure 1). In the remaining tissue, foci of cystic atrophy was present in 100%, stroma in 91%, inflammation in 82% and HGPIN in 36% of patients.

For the 9 patients with lesions > 0.5cc, PE and slope are given in Table 3. The increase in DCE MRI measures with normalization was significantly higher for the 3+3 cancers than the 4+4 cancers (p<0.007). All measures increased as compared to normal peripheral zone and the separation between grades increased, but did not reach significance.

Discussion

This study illustrates the heterogeneity of benign and cancerous tissues within the prostate. In particular, foci of high Gleason Grade (≥4+4) cancer contained a significantly higher percentage of cancer tissue and less benign tissues than Gleason Grade 3+3 foci. Normalizing DCE MRI measures to the concentration of cancer increased the values in comparison to healthy tissue and increased the separation of values between Gleason Grade 3+3 and 4+4 cancers. These differences in concentration and DCE MRI values between grades need further investigation.

Acknowledgments ACS: MRS-0508701-CCE, NIH: P50CA89520, RO1 CA111291.

Table 3 – PE and Slope Before and After Normalization for Concentration

[% normal PZ]	Grade 3+3 [n=5]		Grade 4+4 [n=4]	
	PE	Slope	PE	Slope
Measured	106±3%	161±41%	104±4%	145±30%
Normalized	112±9%	202±56%	105±6%	156±37%
Enhancement Increase[x-fold]	1.8±0.5*	1.8±0.5	1.3±0.3*	1.3±0.3

* P<0.007