

DTI at different b-values in kidneys in children with unilateral pyelonephritis

C. Testa¹, L. Miglio², D. N. Manners¹, C. Tonon¹, E. Malucelli¹, B. Barbiroli¹, A. Pasini², G. Tani², and R. Lodi¹

¹MR Spectroscopy Unit, Department of Internal Medicine, Aging and Nephrology, University of Bologna, Bologna, Bo, Italy, ²Paediatric Radiology Unit, Department of Woman, Child and Adolescent Health, University of Bologna, Bologna, Italy

Introduction

DTI can evaluate functionality and morphology of kidneys because of their radially oriented tubular structures. Perfusion probably contributes to apparent diffusion in particular at low b-values [1]. The aim of this study was to evaluate the ability of DTI to assess renal damage in patients with unilateral chronic pyelonephritis induced by vesicoureteral reflux, a condition that damages medulla and successively glomeruli in the cortex.

Methods

The study population consisted in 12 patients (7 males; mean age: 10 years, range 6-17 years) affected by unilateral pyelonephritis assessed by renal scintigraphy (Tc^{99m} -DMSA). Examinations were performed with a 1.5 T Signa Horizon LX whole-body scanner (General Electric Medical Systems). RF excitation was performed using the body coil and reception using a 8-element phased-array coil designed for adult cardiac imaging. T₂w respiratory triggered SS-FSE and T₁w FSPGR in-phase axial images were acquired. DTI was performed using axial fat-saturated single-shot DTI-EP images. Diffusion gradients were oriented along 6 directions, b-values of 0, 100, 300, 600, 800 s/mm² were used; imaging parameters were: slice thickness 6 mm and gap 1 mm, TR 4000 ms, TE 90 ms, FOV 28 cm for younger and 32 cm for older children, matrix 96x96. Acquisition time of DTI for each b-value was 1'04". Distortions on DT-EPIs were corrected by slice-wise registration of the DTIs onto the first T₂-weighted EPIs using the image registration software FLIRT (www.fmrib.ox.ac.uk/fsl). Using the tensor fitting software DTIFIT to calculate the trace of the diffusion tensor, the mean diffusivity (D) and fractional anisotropy (FA) maps were generated for each b-value. 12 regions of interest (ROI) were defined in D and FA maps to include superior and inferior poles (successively averaged), and the mesorenal region both in the cortex and in the medulla (examples in Figure 1). We calculated mean±SD of D and FA for each ROI and each b value. Differences in D and FA between the affected and the healthy kidney were calculated for each b (Student t-test). Correlations between D, FA and the degree of damage found by scintigraphy were calculated (Spearman test).

Results

Scintigraphy stratified patients into three groups: 1) 6 patients with severe, 2) 4 patients with moderate, 3) 2 patients with mild unilateral functional damage. Healthy kidneys of patients showed D values which decreased with increasing b-value (Fig 2A), as did FA, though less markedly (Fig 2C). D in medulla was lower than in cortex, while FA was 40% higher. In severely affected patients FA values were significantly lower than those in the contralateral kidney for each ROI (Fig 2D) and D was significantly lower only in the cortex of poles (Fig 2B). FA and D in moderately-affected patients were significantly lowered only in the cortex of poles. In the mildly-affected group reduced values of D were found only at higher b-values (600 and 800 s/mm²) in the cortex of poles. Changes of D and FA for each ROI and b-value correlated with the degree of functionality damage found by scintigraphy (p<0.05).

Discussion and Conclusions

Kidney D values strongly depended on the b-value probably because of perfusion contributes at low b-value, as noted elsewhere [1]. FA discriminated values from cortex and medulla better than D [2]; nevertheless the dependence of FA on b-value has not been theoretically explained yet. Unilateral fibrotic damage to the kidney can be detected by both D and FA values: both parameters decrease in the presence of fibrosis with respect to normal values; moreover the degree of abnormality agrees with scintigraphic findings. At higher b-values abnormal D/FA values can be detected even in pyelonephritis patients with mild/small functional impairment.

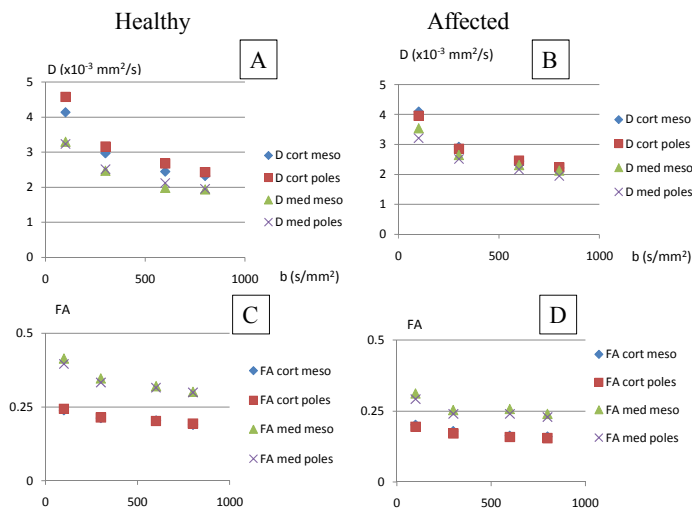



Figure 2. Graph of D and FA values vs b-values in the 12 healthy kidneys (A,C); and in the 6 severely affected kidneys (B, D).

Figure 1. Example of ROIs within the medulla of healthy (right) and affected (left) kidney in the FA map.



[1]Muller MF, Prasad PV, Edelman RR. Eur J Radiology 1998;26:297-303.

[2]Kataoka M, Kido A, Yamamoto A et al. J Mag Res Imag 2009; 29: 736-744.