

Detecting Real-Time Regional Myocardium Strain Changes Using Fast Strain-Encoded (FSENC) MRI

A. A. Harouni¹, T. A. Basha¹, M. L. Shehata², and N. F. Osman^{1,2}

¹Electrical and computer Engineering, Johns Hopkins University, Baltimore, MD, United States, ²Department of Radiology, Johns Hopkins University, Baltimore, MD, United States

Introduction: Dynamic changes in cardiac structure and function are usually examined by real-time imaging techniques such as angiography or echocardiography. Recently, MRI has proven many advantages compared with these established cardiac imaging modalities. Many techniques have been proposed for real-time interactive cardiac MR imaging [1]. However, most of these techniques are limited to only the anatomical information. Real-time functional imaging can be of significant importance to track functional changes in specific cardiac tests or maneuvers like stress test and valsalva exercises. Unfortunately, real-time functional imaging was always difficult to develop because of the relatively long processing time needed to obtain the functional information from the cardiac images. In [2], Pan et al., proposed a new fast method for longitudinal strain quantification in the myocardium. In this work, we propose to use this functional imaging technique in real-time associated with fully automated segmentation algorithm, which provides online anatomical and functional information of regional myocardial regions.

Methods: Strain-Encoded (SENC): SENC is a recently developed method for directly measuring myocardial strain [3]. In SENC, tagging pulses are applied to create a sinusoidal pattern in the slice selection direction. While the tissue deforms, the tagging frequency changes into higher or lower frequency. For each cardiac phase, two images are acquired at two different z-encoding frequencies. Then, by combining these two images using the center-of-mass method, local longitudinal strain can be quantified [3]. In [2], Pan et al., proposed an accelerated version of the SENC technique in which the whole functional cine images can be acquired in one cardiac cycle. This acceleration is achieved by localizing the tagging pulses around the heart and thus reducing the FOV. Then multi-shot spiral acquisition is used to fill the k-space.

Flip Angle Optimization: Tagging is a temporary effect since it fades through time due to T1 relaxation. To compensate for this signal loss, Stuber et al. proposed increasing the excitation flip angle gradually through time in order to maintain uniform signal intensity through time [4]. In [2], the last flip angle was set to maximum angle allowed by the scanner since it was not required to reserve the signal for subsequent acquisition cycles. However, in this work, the pulse sequence is repeated over the consecutive cardiac cycles, which necessitates optimizing the last flip angle value to get good signal during first cardiac cycle and, while leaving enough magnetization that can be tagged in the next cycles. We implemented numerical simulations similar to the work done in [4]. Fig. 1 shows that the best signal intensity can be obtained at last flip angle of 25° to 35°.

Myocardial Tracking: In order to measure the strain inside a specific voxel through time despite the myocardium motion caused by the breathing, a tracking algorithm for the myocardium is necessary. We used the automatic myocardial segmentation technique proposed in [5], where we segment the long-axis four-chamber view into eight regions (five LV Septum and three RV) that can be tracked through time. Then, the average strain is calculated for each region through time

Experiments: 20 normal volunteers were scanned using a dynamic fast-SENC protocol on a clinical 3T MR whole-body system (Gyrosan Intera; Philips Medical System, Best, The Netherlands) using a six-channel phased array cardiac coil. Each volunteer was scanned twice: one during free breathing, and another while holding his breath for as long as he can, to simulate a stress test, then resume breathing gradually. During that, the dynamic scan is running. For each cardiac cycle, data was instantaneously transferred from the scanner to a workstation on which regional strain is quantified and displayed. The following acquisition parameters were used: FOV=256×256mm²; Excited region width=200mm; last flip angle=30°; slice thickness=10mm; in-plane resolution=4×4mm²; multi-shot spiral acquisition with TFE factor=3, acquisition window=7msec, Temporal resolution=30msec. Depending on the heart rate, 17-25 cardiac phases were acquired per cardiac cycle, covering the whole cardiac cycle. To improve the SNR of the result image, the protocol ran every other heartbeat in order to give more time for the magnetization vectors to recover [6]. The total scan time was 35-40 sec.

Results and Discussion: Fig. 2 shows five LV segments with corresponding circumferential strain curves for one of the cardiac cycles. Fig. 3, 4 show the tracking of strain through 20 consecutive cardiac cycles for mid-LV, mid-septal and RV-basal segments of one of the volunteers. Fig. 3 confirms the clinical findings, where the mid-LV strain is always greater than the mid-septal strain. Fig. 4 compares RV-basal strain for free-breathing and breath hold-scan, we notice that during breath-hold, the RV peak-strain is constant (around -17%) as the RV is opposed by high pressure in the lungs. On the other hand, during free-breathing the RV peak-strain changes periodically with the breathing motion.

Conclusion: We proposed a new real-time functional imaging method that enables instantaneous tracking of regional function changes of the myocardium. This can be useful in real-time monitoring of cardiac strain changes during either stress test, valsalva exercise or interventional operations.

References: [1] Guttman, M. et al, MRM 50-2:315 (2003). [2] Pan L. et al, MRM 55-2, 386 (2006). [3] Osman N. et al, MRM 46: 324-10 (2001). [4] Stuber, M. et al, MAGMA 9-1, 85 (1999). [5] Harouni A. et al, ISBI 827(1009). [6] Basha, T. et al, JCMR 10 2008.

Acknowledgment This work was supported in part by the following grants NHLBI R01HL072704, NIH 1P50HL08946, and R01HL61912.

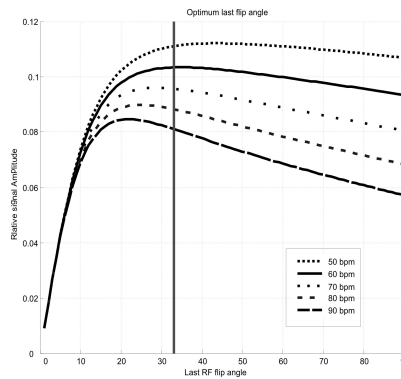


Fig.1: Relative signal intensities plotted versus last flip angle for different heart rates. Vertical line show optimum flip angle of 33° for heart rate of 60 beat per minute.

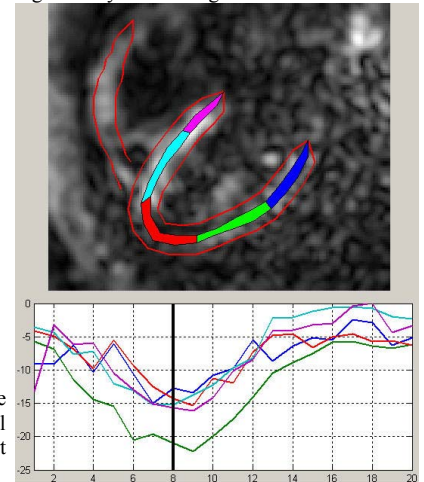


Fig.2: Automatic segmentation of left and right ventricle. Five LV segments: basal-LV, mid-LV, apex, mid-septal, and basal-septal shown in blue, green, red, cyan, and magenta with corresponding strain curves for one of the cardiac cycles.

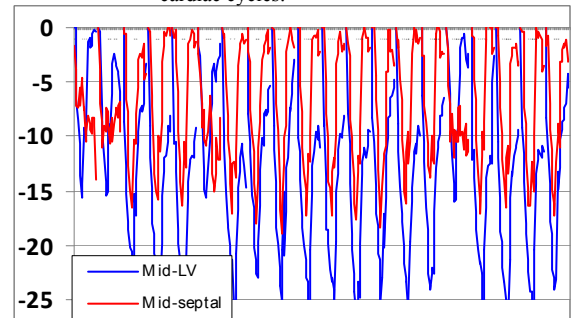


Fig.3: Strain curves for the Mid-LV (blue) and Mid-septal (red) segment for 20 cardiac cycles.

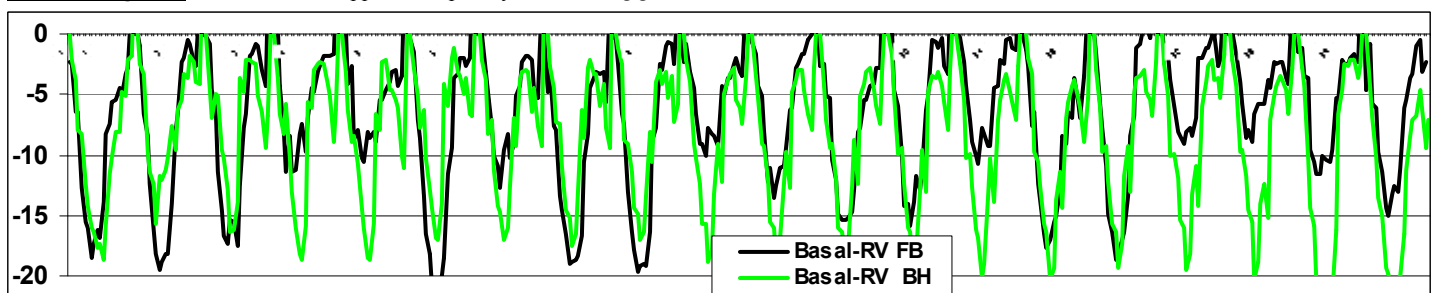


Fig.4: Strain curves for the RV- Basal segment for 20 cardiac cycles for free breathing FB (Black) and breath hold BH in (light green).