

# Assessment of the early response to chemotherapy with diffusion-weighted MRI in advanced lung cancer patients-comparison with FDG-PET-

T. Tsuchida<sup>1</sup>, M. Morikawa<sup>2</sup>, Y. Umeda<sup>2</sup>, M. Sasaki<sup>3</sup>, T. Kamibayashi<sup>1</sup>, and H. Kimura<sup>1</sup>

<sup>1</sup>Dept. of Radiology, University of Fukui, Fukui, Japan, <sup>2</sup>Dept. of Respiratory Medicine, University of Fukui, Fukui, Japan, <sup>3</sup>Dept. of Thoracic Surgery, University of Fukui, Fukui, Japan

## Introduction

In advanced lung cancer patients, systemic chemotherapy is usually applied for their treatment. For the effective therapy, the assessment of early response to therapy is required to decide whether the current treatment regimen should be continued or changed. Although the measurement of tumor size with computed tomography (CT) is widely used for the assessment of therapy, change in size against the therapy is insensitive and is not suitable for the evaluation of early response. As the preferable functional imaging, positron emission tomography with fluorine-18 fluorodeoxyglucose (FDG-PET) is reported to be useful for the assessment of early response to therapy. However, the institution where FDG-PET is available is limited and the more accessible modality is desired.

## Purpose

The purpose of this study is to examine the utility of diffusion-weighted MRI image (DWI-MRI) for the assessment of early response to chemotherapy in patients with advanced lung cancer by comparing FDG-PET.

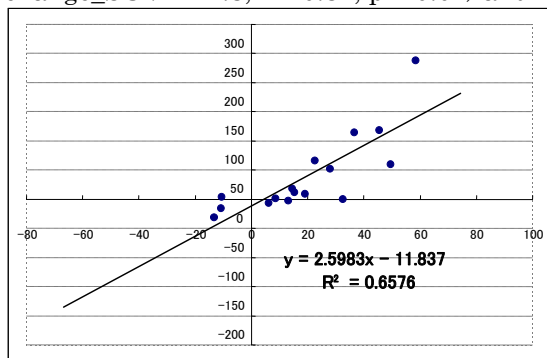
## Methods

Twenty-two patients with histologically proven lung cancer patients (7 SCLC (small cell lung ca.), 10 scc (squamous cell ca.), 4 adenoca., and 1 LCNEC (large cell neuroendocrine cell ca.) were included in this study. All patients received MRI, FDG-PET, and CT examination before and after 1 cycle of chemotherapy.

MRI examination was performed with 1.5-tesla MR system (Signa Excite, GE Healthcare). DWI-MRI was performed with echo planar imaging sequence with short T1 inversion recovery (STIR) fat suppression. Image acquisition was performed in chest region where primary lesion was included. The parameters for data acquisition were as follows: FOV = 420mm, Matrix size = 128 x 128, TR/TE/TI = 5000/60/150, NEX = 6, slice thickness/gap = 7/0 mm, b-value = 800. FDG-PET examination was performed with PET-CT scanner (Discovery LS, GE Healthcare). Image acquisition was performed 60 minutes after the intravenous injection of 185 MBq of FDG. Acquired data was reconstructed with iterative reconstruction algorithm and reconstructed images were converted to SUV (standardized uptake value) image with injected dose of FDG and patients body weight. ADC (apparent diffusion coefficient) on DWI-MRI, SUV on FDG-PET, and maximum diameter on CT in the primary lesion were measured in each case before and after chemotherapy and % change was calculated. As an index of the response to therapy on CT, RECIST (Response Evaluation Criteria in Solid Tumors) was applied. In this criterion, less than 30% decrease and 20% increase of diameter was defined as SD (stable disease). As the index on FDG-PET, EORTC (European Organization for Research and Treatment of Cancer) recommendation was applied. In this criterion, more than 15% decrease of SUV was defined as responder. On MRI, as an appropriate index does not exist, cut-off value for responder, which was shown in results section, was estimated from the relationship between % change of ADC and SUV. For the prognostic indicator, PFS (progression free survival) between responder and non-responder which was defined as SD on CT were compared.

## Results

The significant relationship of the % change between SUV and ACD was observed ( $\% \text{ change\_ADC} = 2.6 \times \% \text{ change\_SUV} + 11.8$ ,  $r = 0.81$ ,  $p < 0.01$ ) and from this relationship, the cut-off value for responder in ADC was decided to 25%. In RECIST, 16 patients were categorized as SD. Of them, 12 patients on FDG-PET and 8 on DWI-MRI were categorized as responder. PFS (unit:days) between responder and non-responder on FDG-PET and DWI-MRI showed significant difference (143 +/- 50 vs. 70 +/- 42 on FDG-PET,  $p=0.04$ ; 154 +/- 55 vs. 70 +/- 42 on DWI-MRI,  $p = 0.02$ ). No significant difference of PFS between FDG-PET and DWI-MRI in responder or non-responder was observed.



## Discussion

In this study, DWI-MRI and FDG-PET demonstrated the ability for the assessment of early response to chemotherapy. SD categorized on CT is the most concerning status for clinician whether the current therapy should be continued or changed; therefore more sensitive method is required. FDG-PET is well known to exhibit the glycolytic activity in cancer cell and with respect to functional imaging the advantage of early assessment to therapy is well established. On the other hand, DWI-MRI is also reported to have a possibility for the early assessment to chemotherapy in animal model. The mechanism of the change of ADC in early phase of chemotherapy is suggested to be the decrease of cell density before changing macroscopic size. MRI is highly accessible compared to FDG-PET and free from radiation exposure. With respect to these advantages, this kind of assessment will be distributed to not only lung cancer but also other solid tumors.

## Conclusion

DWI-MRI will be a promising tool for the assessment of the early response to chemotherapy in advanced lung cancer patients.