

Non-invasive imaging of diffuse liver disease using water T2 and fat fractions obtained from a breath hold radial GRASE method

M. I. Altbach¹, C. Graff², C. Huang³, V. Abraham¹, S. W. Squire¹, D. Bruck⁴, K. Ray⁴, and T. Boyer⁴

¹Radiology, University of Arizona, Tucson, Arizona, United States, ²Division of Imaging and Applied Math, U.S. Food and Drug Administration, Silver Spring, Maryland, United States, ³Mathematics, University of Arizona, United States, ⁴Medicine, University of Arizona, United States

Introduction: The diagnosis of inflammation, fibrosis, and steatosis is important in the characterization of diffuse liver disease such as Hepatitis C, non-alcoholic steatosis (NASH), and cirrhosis. Currently the diagnosis of these pathologies requires a liver biopsy which is an invasive procedure with associated morbidity and cost and in some cases subject to sampling errors. Non-invasive imaging techniques including Magnetic Resonance Elastography and Diffusion Weighted MRI have been sought as a means to provide a non-invasive alternative for the diagnosis of diffuse liver disease [1,2]. One of the drawbacks of these techniques is that the presence of fat (typically found in the liver as a result of the above mentioned liver pathologies) is a confounding factor in the determination of parameters that otherwise can be associated with inflammation and fibrosis.

Recently our group developed a novel radial gradient and spin-echo (GRASE) method which provides T2 and fat-water mapping with the advantage that the T2 estimation is independent of the presence of fat [3,4]. The method is fast (data for T2 and fat-water mapping are acquired in a breath hold) and it provides high spatial resolution and motion insensitivity. These conditions make it ideal for liver imaging. In this work we provide the first results in patients with various liver conditions and compare T2 and fat-water information to biopsy results.

Methods: A radial GRASE pulse sequence was implemented on a 1.5T GE Signa NV-CV/i scanner. In the radial GRASE method used in this study four gradient echoes were collected at each SE period. Data were acquired on a breath hold (18 s) with BW=±125 kHz, ETL=12, matrix size=256×192, TR=1s, NEX=1. Time shifts between the SE points and the four gradient echoes corresponded to fat-water phase shifts of (-5π/2, -π/6, π/2, 7π/6).

The procedure used for T2 and fat-water mapping is as follows. First, the four gradient echoes are used to obtain initial fat-water estimates, corrected for the effects of field inhomogeneities, using an iterative fat-water decomposition method [5]. For T2 estimation we use the gradient echoes that are closest to the SE point to generate images at various TE_{eff} as described recently in [3]. T2 of the water component, T_{2w}, and the final fat-water estimates were then calculated by fitting the signal intensity of every pixel in the TE_{eff} images (i.e. 12 images) to:

$$|S(TE_{eff})| = \left| I_w e^{-\frac{TE_{eff}}{T_{2w}}} + I_f e^{-\frac{TE_{eff}}{T_{2f}}} e^{iC_s \Delta_n} \right| \quad (\text{Eq. 1})$$

In Eq. 1, I_w and I_f are the water and fat estimates and T_{2f} is the T2 of fat. C_s is the chemical shift between fat and water and Δ_n is the time shift of the echo (used for T2 estimation) relative to the SE point. Both C_s and Δ_n are known quantities. T_{2f} is treated as a known constant in Eq. 1. In vivo T_{2f} was estimated for each subject using the average T_2 value from regions in the body that contain mostly fat (e.g. the subcutaneous fat layer) using the

$$\text{single exponential decay model: } |S(TE_{eff})| = \left| I \cdot e^{-\frac{TE_{eff}}{T_2}} \right| \quad (\text{Eq. 2})$$

The T_{2w} histograms were generated from all slices imaged (8-10 slices) from a segmented region containing just the liver. Blood vessels within the liver were automatically segmented out by applying a threshold to the signal intensity in the water image.

Results: To test the ability of the technique to detect diffuse liver disease, we imaged four patients who had liver biopsies within a week of the MRI scan and four normal subjects (without any condition leading to suspicion of liver disease). Before imaging patients we evaluated the dependence of the T_{2w} distributions with eating stages in normal volunteers. As shown in Fig. 1, the T_{2w} histograms for the same subject (acquired the same day) at 0, 1, 2, and 8 hours after eating are very similar indicating that the method is reproducible and insensitive to noise and it does not require restrictions such as fasting.

Representative T_{2w} histograms for subjects with confirmed diagnoses of Hepatitis C (green) and cirrhosis (red) are shown in Fig. 2 together with data for a normal subject. Note that the T_{2w} distribution for the subjects with liver disease is broader than for the normal subject with T_{2w} tailing to higher values as the severity of disease increases. A summary of the T_{2w} and %fat statistics (mean and variance) for the subjects included in the study is given in Table 1 along with biopsy results (when available). There are significant differences in the T_{2w} variances (σ^2), consistent with the difference in the T_{2w} histograms shown in

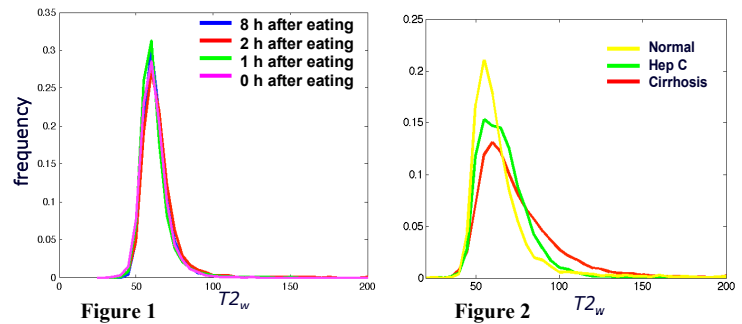


Fig. 2 All normal volunteers (subjects 5-8 in the table) as well as the subject with a normal biopsy (subject 4) have smaller T_{2w} σ^2 compared to the subjects with abnormal biopsies (subjects 1-3). In the latter group, T_{2w} σ^2 increase with the severity of the diagnosis (i.e., higher inflammation and fibrosis). Note also that the subjects with Hepatitis C and cirrhosis show a higher mean %fat than normals, which is common in patients with these conditions. Interestingly, subject 3 showed a mean %fat of 44.1% which is consistent with the biopsy report of *marked steatosis*. The T_{2w} σ^2 for subject 3 (177.1) is lower than for the other patients which is also consistent with the biopsy findings of mild inflammation (I=1) and no fibrosis (F=0).

Conclusion: A novel radial GRASE method was evaluated in patients suspected of liver disease and in normals. The advantage of the technique is that T2 of the water component is determined independently of the fat component which is typically a confounding factor in the non-invasive characterization of diffuse liver disease. Results indicate that the variance in T_{2w} is higher in subjects with diffuse liver disease with variances increasing with the severity of disease. The %fat, obtained from the same radial GRASE data set, provides information on liver steatosis (independently of other abnormalities such as inflammation and fibrosis). This novel method is fast and may prove to be a valuable clinical tool for the non-invasive imaging of the liver.

Acknowledgement: NIH grants CA099074 and HL085385 and the ORISE post-doctoral fellowship program. **References:** [1] Rouviere O et al, Radiology 240: 440, 2006. [2] Taouli B et al AJR, 189:799, 2007 [3] Li Z, Graff C et al, MRM 61:1415, 2009. [4] Graff C et al ISMRM 17, 202, 2009. [5] Reeder SB et al MRM 51:35, 2004.