

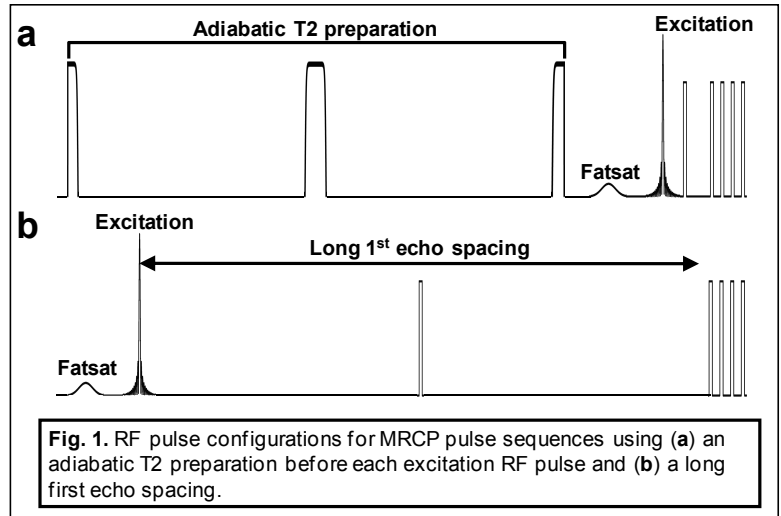
## Three-dimensional MRCP with Reduced RF Power Deposition

J. P. Mugler, III<sup>1</sup>, W. Horger<sup>2</sup>, and B. Kiefer<sup>2</sup>

<sup>1</sup>Radiology, University of Virginia, Charlottesville, VA, United States, <sup>2</sup>Siemens Healthcare, Erlangen, Germany

**Introduction:** MR cholangiopancreatography (MRCP) is routinely used to assess the bile and pancreatic ducts. The heavily T2-weighted images required for MRCP are typically created by using a fast- or turbo-spin-echo pulse sequence (e.g., RARE, FSE, TSE) with a very long echo time [1]. Although such a pulse sequence is effective for achieving the desired image contrast, the associated power deposition is relatively high due to the large number of high-flip-angle refocusing RF pulses required to yield the very long echo time of several hundred milliseconds. As a result, regulatory limits on power deposition may be exceeded, particularly at 3T. The flip angle of the refocusing RF pulses can be reduced below 180° to meet power deposition requirements, but a substantial flip-angle reduction, as sometimes required, compromises image quality. Thus, there is a need for a technique with fundamentally lower power deposition that allows a flip angle of approximately 180° to be maintained for the refocusing RF pulses, thus routinely providing high image quality. The purpose of this work was to explore two different approaches for achieving this goal.

**Methods:** The basic strategy was to create strong T2 weighting without using a train of closely-spaced refocusing RF pulses, and then to sample this strong T2 weighting using a partial-Fourier spin-echo-train, thus reducing the power deposition compared to a standard (full-Fourier) acquisition by up to approximately 50%. The two approaches for creating strong T2 weighting included: (1) an adiabatic, T2-preparation pulse [2] applied just before the excitation RF pulse of each spin-echo train (Fig. 1a); and (2) a very long echo spacing (ESP) for the first echo interval of the spin-echo-train acquisition (Fig. 1b). A T2 preparation in conjunction with MRCP was investigated by Busse et al as a means to improve suppression of the signals from fat and small blood vessels [3]. The two approaches were implemented in a SPACE single-slab 3D-TSE pulse sequence, and evaluated in 4 healthy volunteers on a 1.5T scanner (Avanto, Siemens) and in 2 healthy volunteers (one of which was imaged on 3 separate occasions) on a 3T scanner (Trio, Siemens). The T2-preparation and long-first-ESP pulse sequences were compared to the standard MRCP pulse sequence (fat-suppressed, full-Fourier, turbo spin echo) for the respective scanners. In all cases, 3D navigator-based respiratory-triggered acquisitions were acquired during tidal respiration. Aside from the modifications to the echo train, all other parameters (e.g., FOV, matrix size, parallel acceleration factor) were identical for a given comparison of the proposed approaches to the standard pulse sequence. The time allocated to the T2 preparation or long first ESP ranged between 100 and 400 ms, resulting in a total effective echo time of 308-512 ms. The effective echo time for the standard MRCP sequences was 694-705 ms. Informed written consent was obtained from all subjects prior to imaging.

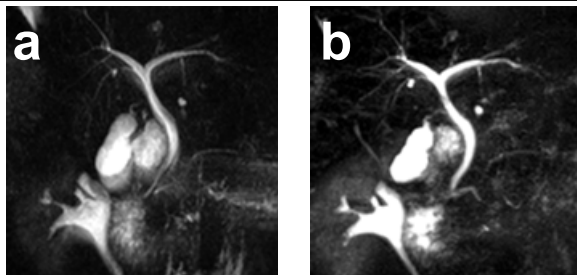


Aside from the modifications to the echo train, all other parameters (e.g., FOV, matrix size, parallel acceleration factor) were identical for a given comparison of the proposed approaches to the standard pulse sequence. The time allocated to the T2 preparation or long first ESP ranged between 100 and 400 ms, resulting in a total effective echo time of 308-512 ms. The effective echo time for the standard MRCP sequences was 694-705 ms. Informed written consent was obtained from all subjects prior to imaging.

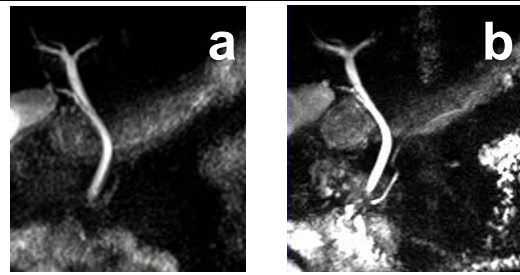
**Results:** Compared to the standard MRCP protocol, the T2-preparation and long-first-ESP approaches provided approximately 25% and 40% reductions in power deposition, respectively. The T2 preparation was markedly less effective than a long first ESP in reducing power deposition due to the significant power deposition associated with the adiabatic preparation pulse. The total effective echo time that provided the desired image contrast for the T2-preparation and long-first-ESP approaches was approximately 400 ms less than that for the standard MRCP pulse sequence, likely due to effect of echo spacing on the signal decay of certain relevant tissues, such as fat [3]. Both the T2-preparation and long-first-ESP approaches yielded MRCP results with quality comparable to that for the standard MRCP pulse sequence, as illustrated in Figs. 2 and 3.

**Conclusions:** T2 preparation or long first echo spacing combined with partial-Fourier acquisition permits the power deposition to be reduced by 25%-40% compared to that for a standard MRCP pulse sequence, while providing image quality comparable to that for the standard method. This approach will be valuable for addressing power-deposition limitations of MRCP at 3T, and will permit more consistent MRCP image quality to be achieved. Future studies will focus on evaluation of the proposed methods in subjects with disease.

**References:** 1. Yeh BM et al. Radiographics 2009; 29:1669. 2. Mugler JP et al. JMRI 1991; 1:731-737. 3. Busse RF et al. Proc ISMRM 14 (2006); 392.



**Fig. 2.** Maximum intensity projections from 3D MRCP data sets acquired at 1.5T using (a) the standard pulse sequence (effective TE 694 ms) and (b) a T2 preparation (200-ms preparation time, total effective TE 312 ms).



**Fig. 3.** Maximum intensity projections from 3D MRCP data sets acquired at 3T using (a) the standard pulse sequence (effective TE 705 ms) and (b) a long first ESP (200-ms first ESP, total effective TE 308 ms).