

Prominent citrate predicts malignant progression of low-grade astrocytomas in children

A. C. Nagasunder¹, M. Laskov², A. Joseph², A. Panigrahy^{1,3}, G. Dhali², J. L. Finlay², I. Gonzalez-Gomez², M. D. Krieger⁵, M. D. Nelson¹, and S. Bluml^{1,6}

¹Department of Radiology, Childrens Hospital Los Angeles, Los Angeles, California, United States, ²Childrens Center for Cancer and Blood Diseases, Childrens Hospital Los Angeles, Los Angeles, California, United States, ³Department of Radiology, Childrens Hospital of Pittsburgh of UPMC, Pittsburgh, Pennsylvania, United States, ⁴Department of Neuropathology, Childrens Hospital Los Angeles, Los Angeles, California, United States, ⁵Department of Neurosurgery, Childrens Hospital Los Angeles, Los Angeles, California, United States, ⁶Rudi Schulte Research Institute, Santa Barbara, California, United States

Purpose: To determine whether *aggressive* pediatric low-grade II astrocytoma have metabolic features that distinguishes them from *stable* grade II astrocytoma.

Methods: Medical records and MRS studies of pediatric patients with astrocytomas were retrospectively reviewed. Five patients were identified with *low-grade astrocytomas* (WHO II) and no clinical or radiological progression over at least two years of follow-up (*indolent-LGA*). Six patients were identified with *low-grade astrocytomas* with progression within two years after diagnosis (*aggressive-LGA*). Twelve patients with high-grade (WHO III) astrocytomas (HGA) and poor outcome were also included in this analysis. All *indolent-LGA* subjects were alive whereas all *aggressive-LGA* and HGA subjects have succumbed to their disease at the time of the completion of this study. MR spectra were acquired with single-voxel PRESS (TE=35ms) on a 1.5T MR scanner. Fully automated LC-Model software (S. Provencher, Ontario, Canada) was used to determine absolute concentrations (mmol/kg) of metabolites.

Results: An MR spectrum of a grade II astrocytoma shows a moderate choline (Cho) peak. A signal consistent with citrate (1) is detectable at ≈ 2.6 ppm (**Fig. 1**). There were no statistical significant differences between all grade II and grade III tumors. Citrate (Cit) was significantly higher in *aggressive-LGA* than in *indolent-LGA* and NAA was lower in *aggressive-LGA* (**Fig. 2, Tab.**). There was no significant difference in choline between these two subgroups.

Discussion: This study addresses the need to identify markers that would allow pediatric neuro-oncologists to predict which tumors among low-grade (II) astrocytomas have the potential for malignant progression. Elevated citrate in poor outcome LGA may reflect the capability of some LGA to abnormally increase glycolysis to support increased proliferation (Warburg effect). Lower NAA is consistent with a lower density of residual normal neurons/axons within *aggressive-LGA*. Albeit, Cho is generally higher in higher grade lesions, it did not correlate with outcome. The above observations are consistent with recent MRS findings in pontine gliomas. Pontine gliomas, often low-grade at diagnosis, but then with inevitable progression and 100% mortality generally show high citrate levels whereas Cho levels are moderate (1,2).

Conclusion: Elevated citrate and low NAA may predict malignant progression of low-grade astrocytomas.

Acknowledgment: Rudi Schulte Research Institute, Ian's Friends Foundation, Thrasher Research Fund, National Childhood Cancer Foundation.

References: 1.Seymour et al. AJNR 29: 1006-1011, 2008. 2. Panigrahy et al. Neuro Oncol 10:32-44, 2008.

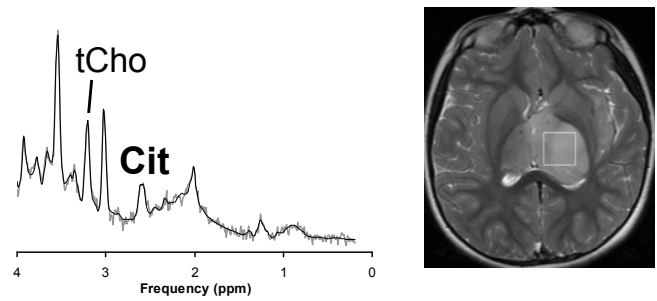


Fig. 1: Short TE PRESS spectrum and MRI indicating the region of interest of a biopsy-proven grade II astrocytoma at initial presentation. The lesion progressed and the patient died 17 months after initial diagnosis.

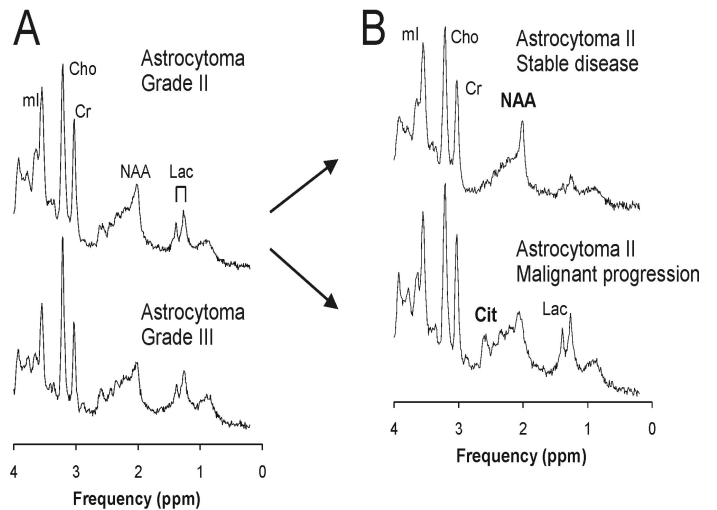


Fig. 2A: Averaged spectrum of all grade II (upper trace) and all grade III astrocytoma (lower trace). **2B:** When low-grade astrocytomas were subdivided according to clinical outcome, citrate (Cit) and N-acetyl-aspartate (NAA) were significantly different. Cr = creatine, ml = myo-inositol.

Table: Concentrations (mmol/kg) of pediatric astrocytomas.

	Astrocytomas with stable disease	Astrocytomas with disease progression within two years after initial diagnosis	
	Grade II (n=5)	Grade II (n=6)	Grade III (n=12)
[Cit]	0.6±0.4	4.1±1.2**	3.2±2.7*
[NAA]	3.2±0.8	0.6±0.7**	1.6±0.8*
[Cr]	7.1±1.5	7.6±3.2	6.1±2.3
[tCho]	3.0±1.3	3.5±1.3	3.7±1.8
^a [Lac]	1.1±0.9	4.8±4.4	2.5±2.3

*p<0.01, **p<0.001 versus *indolent-LGA*, ^aLac conc. is reported in mmol/liter volume.