

Naming Errors and Gray Matter Structural Variations

K. McMahon¹, A. Holmes², S. Heath², A. Angwin³, L. Nickels⁴, E. McKinnon², S. Van Hees², and D. Copland^{2,3}

¹Centre for Magnetic Resonance, University of Queensland, Brisbane, Queensland, Australia, ²UQ Centre for Clinical Research, University of Queensland, Australia,

³School of Health and Rehabilitation Sciences, University of Queensland, Australia, ⁴Macquarie Centre for Cognitive Science (MACCS), Macquarie University, Sydney, NSW, Australia

Introduction

Word production is a complex process involving processing conceptual representation, lexical access, retrieving phonological forms and articulation; but it is usually effortless in healthy subjects [1,2]. As age increases, the frequency of naming errors also increases. The picture naming difficulties that occasionally occur may be categorised as unrelated (e.g. see kite and respond shoe), semantic (e.g. bird for nest), phonological (e.g. window for windmill) and visual perceptual errors (e.g. rope for pretzel). The neural correlates for naming errors have not been adequately characterised for healthy cohorts. This study examines the individual differences in gray matter (GM) volume associated with naming difficulties in healthy elderly controls.

Methods

23 healthy controls consented to participate in the study, with a mean age of 57.1 (SD 12.1, 12 females). Naming errors were determined from a large battery (476) of pictures (sourced from the Hemera digital photographic database and other royalty free stock photographs). Errors were classified as unrelated, semantic, phonological, or visual perceptual. The healthy cohort made between 17-111 errors in naming (mean 53.7), of which on average 13% were unrelated, 50% semantic, 2% phonological and 35% visual perceptual. MRI scans were performed on a 4T Bruker Medspec. A high resolution 3D T1-weighted MPRAGE sequence (TI 900ms, TR 2200ms, TE 2.99ms, resolution 1.0 x 1.0 x 1.0mm) was acquired. The T13D scans were normalised, bias corrected, segmented and smoothed using the VBM toolbox in SPM5. A general linear model analysis was performed covaried with the mean number of errors per category per subject. Due to significant correlations between these components and age, years of education and gender, we included these variables as nuisance regressors in both analyses. We conducted a whole brain analysis in which we adopted a voxel-wise alpha threshold of $p < .001$, with a cluster extent threshold of 25, taking into account the non-stationary smoothness of the data [3]. The results were also considered excluding those areas that also covaried strongly with age, through exclusion masking with probability $p < 0.05$.

Results

Increased unrelated errors were associated with decreased gray matter volume in right frontal (rectal and medial orbital) gyrus, the caudate bilaterally, and left insula. Similar frontal areas were seen for reduced semantic error rates, as well as right superior frontal gyrus (SFG) and right supplementary motor area (SMA). Increased phonological errors were correlated with significant decreases in gray matter volume in left inferior and middle temporal gyrii (ITG and MTG), bilateral BA 6 (precentral and paracentral gyrii), left precuneus, left postcentral gyrus, right cerebellum, and left inferior frontal gyrus (pars triangularis; IFG). Increasing visual perceptual errors correlated with reductions in left ITG, bilateral superior parietal lobule, left cuneus and right precuneus, right heschl's gyrus, left SFG and right postcentral gyrus (area 3b). See Figure 1. The regions correlated with increased visual processing errors were the only ones completely unrelated to age when using the exclusion masking. Variations in age accounted for the involvement of a number of regions including the left caudate (for unrelated errors), frontal medial region (for semantic errors) and right cerebellum (for phonological errors).

Discussion

The complex process of naming relies on access to several levels of encoded information, and different types of naming errors should reflect different stages in this process, each accessing possibly separable neural sub-networks [1,2]. Increased gray matter volume within several motor and supplementary motor areas was associated with decreasing naming errors for the semantic, phonological and visual perceptual categories, suggesting common motor related articulatory processes, although this finding was not observed for unrelated naming errors. Involvement of the premotor and pre-SMA regions may alternatively reflect their role in executive and attentional processes, and increased activity in these regions is associated with increased naming performance in aphasic patients.[4] Structural differences within fronto-striatal circuitry were implicated in unrelated naming errors, consistent with proposals regarding the role of the subcortex in lexical retrieval, although this involvement appeared to primarily reflect age related changes. Orbitofrontal volume was associated with both unrelated and semantic categories, consistent with the proposal that this region plays a general role in semantic and phonological processing, being involved in both repetition and semantic decision tasks [5]. The left ITG is thought to be involved in lexical selection/lemma representation, but is correlated here with phonological and visual perceptual naming errors. In previous functional studies, this region correlated with word frequency which is typically thought to be at the phonological level [6]. and might be an area involved in feedback between levels.[7,8] This region has been functionally activated when comparing phonemic errors with correct naming in aphasia patients[4]. While the association of the MTG with phonological errors fits well with its assumed role in phonological retrieval [7], involvement of left IFG may reflect its role in resolution of competition in word production, as observed in patient studies [4] or may relate to a more general role in cognitive control and selection [7,9]. Activation in bilateral IFG is seen in both aphasia patients and controls for errors associated with a greater number of alternative names and later age of acquisition [10]. The increased gray matter in occipital-parietal regions suggests relatively improved visual processing in these areas contributing to less visual perceptual errors. This agrees with current models on conceptual preparation areas [1,11] and case studies with lesion patients [11]. This data will hopefully help to inform the normal baseline before cortical reorganization in language recovery in stroke.

References:

1. Indefrey P, Levelt WJ (2004): Cognition 92:101-144.
2. C Price, (2000) J Anatomy. 197(3):335-59.
3. Hayasaka, S., et.al. (2004). Neuroimage 22, 676-687.
4. Fridriksson J et. al. (2009) HBM. 30:2487-2498.
- 5 Noppeney U, Price CJ. Neuroimage (2002) 15(4):927-35.
6. Graves WW et. al. (2007) J Cogn Neuro. 19:617-631
7. Wilson SM et al, (2009) HBM, 30:3596-3608.
8. Dell GS et al. (1997) Psychol Rev. 104: 801-38
9. Schnur et al, (2009) PNAS USA. 106(1):322-7.
10. Postman-Caucheteux WA et al. (2009) J Cogn Neuro. joen.2009.21261
11. Price CJ, et.al (2005) HBM. 25:70-82.

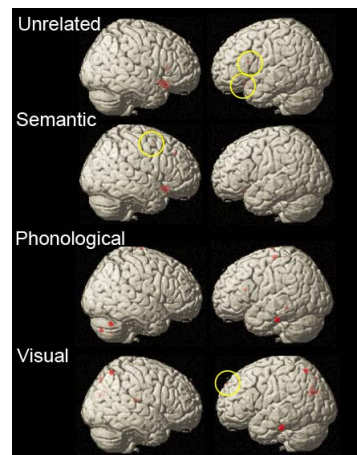


Figure 1: Picture naming errors correlated with gray matter density.