

High Resolution MR Flourescopy

P. Vakil¹, H. J. Jeong², H. Bhat², C. Eddleman³, and T. J. Carroll²

¹Radiology, Northwestern University, Chicago, IL, United States, ²Northwestern University, ³Northwestern Memorial Hospital

Introduction

In CE MRA, for a given FOV, there is a tradeoff between SNR, spatial resolution, and temporal resolution. A high temporal resolution (> 1 frame/second) is necessary for visualizing complex flow patterns in brain AVMs. At the same time, high SNR and spatial resolution are required for small vessel discrimination (< 1 mm). Currently, many 3D protocols have been developed using various under-sampling schemes in Fourier space which serve to increase temporal resolution at the expense of SNR. One example is the “keyhole” technique which initially obtains a high resolution volume but updates only low frequency data on subsequent acquisitions. On the other hand, there are only few reports on 2D acquisitions in CE MRA. When used in conjunction with a static, high resolution MRA, however, 2D acquisitions provide a comprehensive exam. In this study we present a novel 2D MRI pulse sequence with pseudorandom radial sampling (1) and sliding window reconstruction (2) that produces high frame rate (6 frames/sec) CE MR Angiograms, comparable to X-ray DSA, and sufficient SNR for small vessel discrimination.

Materials and Methods:

Image Acquisition

In this ongoing study, patients with angiographically confirmed AVMs underwent a 2D gradient echo sequence immediately prior to X-ray DSA. The raw data was acquired on a 3T Trio (Siemens) MR imaging system with the following protocol: FOV = 220x220mm, TR/TE = 5.44/1.85 ms, $N_{\text{Proj}} = 384$, $N_{\text{RO}} = 384$, receiver BW = 651 Hz/Px, Flip Angle = 30°, asymmetric pseudorandom radial sampling, spatial resolution = 0.57 mm x 0.57 mm, temporal foot print = ~ 2 sec/acquisition, frame rate = 6 frames/sec. We also investigated the appearance of ringing image artifacts visualized as concentric circles about the geometric center of reconstructed images. Artifacts were studied by manipulating TR, view order, and readout spoiler moment magnitude as well as utilizing a rewinder along the readout direction.

Post-Processing

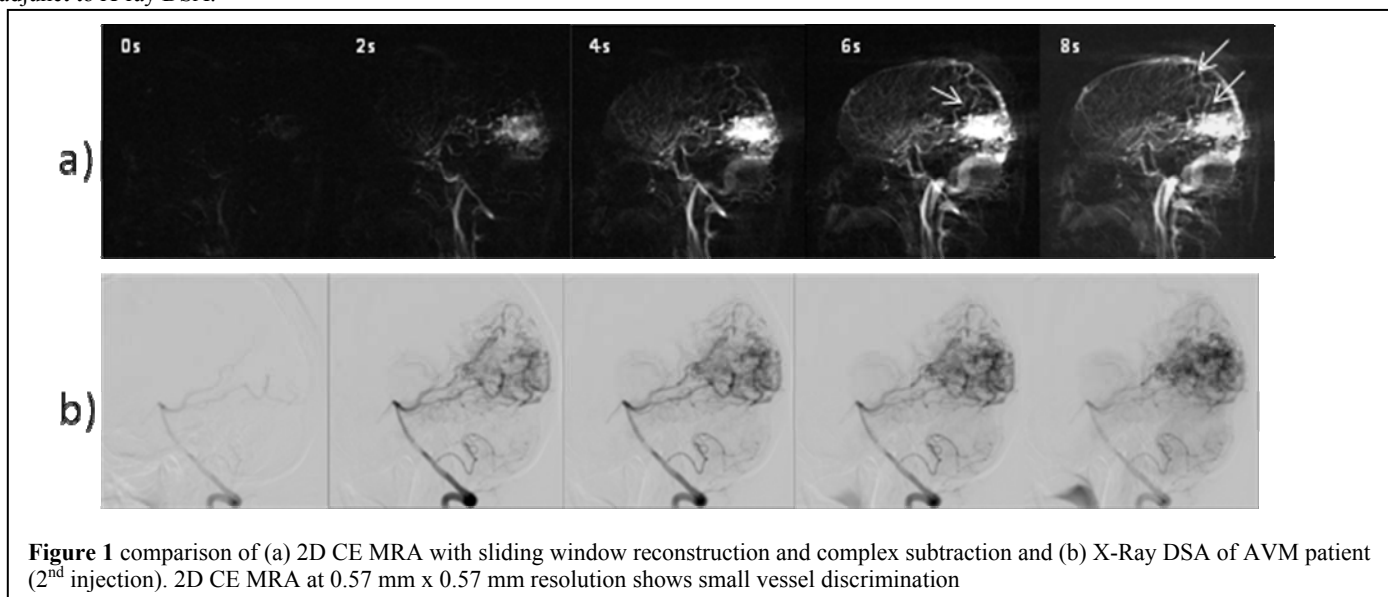
Sliding window reconstruction was performed offline along with complex subtraction using MATLAB. The presence of image artifacts was assessed visually in both image space and k-space.

Results/Discussion

Our protocol produces MR angiograms of a brain AVM (Figure 1a) that correlates with the corresponding X-Ray DSA images (Figure 1b). Flow characteristics of AVM are visualized while small vessels are simultaneously discriminated. Complex subtraction was performed over magnitude subtraction in reconstructed images to prevent loss of flow signal due to differences in phase and magnitude between stationary and flowing magnetization. Inadvertent transverse coherences in k-space were found to be responsible for aforementioned ringing artifacts in reconstructed images. Pseudorandom view ordering and improper transverse magnetization spoiling in each RF interval induced these stimulated echoes; however, application of a rewind gradient along the readout direction as well as a high magnitude spoiling moment sufficiently minimized these artifacts.

Conclusion

Our patient studies demonstrate that our 2D CE MRA protocol with complex subtraction and sliding window reconstruction clearly visualizes the hemodynamics of the intracranial vasculature in the setting of an AVM. Furthermore we resolved the appearance of circular ringing artifacts symptomatic of fast, pseudorandom radial 2D MRA protocols. We believe this new sequence has potential to advance CE MRA as a non-invasive adjunct to X-ray DSA.



References

Cashen TA et al. MRM, 2007. 2) Riederer SJ et al. MRM, 1988. 3) Jeong HJ et al. MRM, 2009