

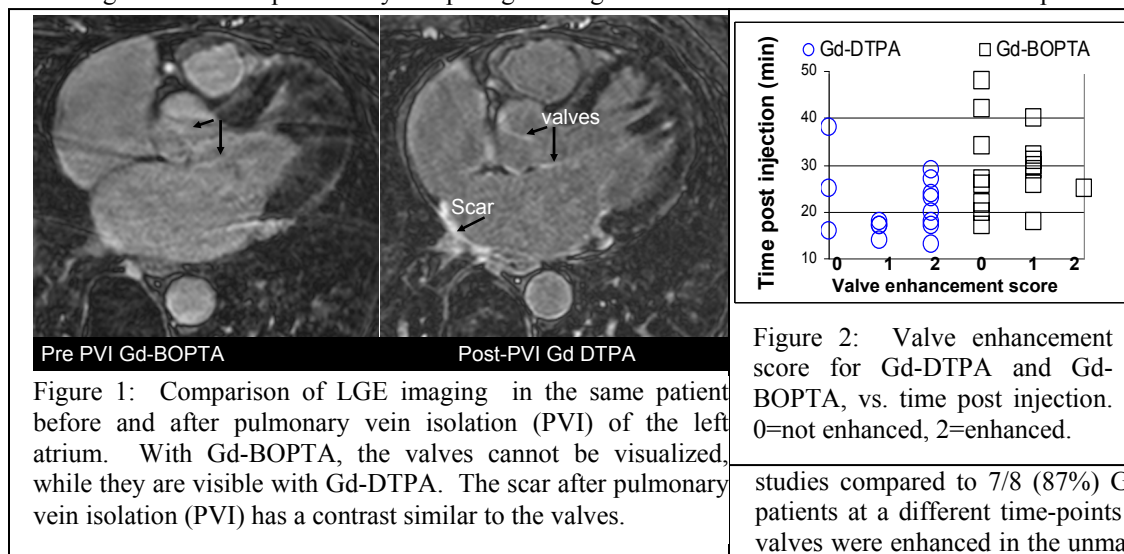
## Comparison of Gd-BOPTA and Gd-DTPA late gadolinium enhancement for visualizing scar, using valve enhancement as a surrogate for scar adjacent to blood

D. C. Peters<sup>1</sup>, R. Nezafat<sup>1</sup>, P. Hu<sup>1</sup>, Y. Han<sup>1</sup>, and W. J. Manning<sup>1,2</sup>

<sup>1</sup>Cardiovascular Division, Beth Israel Deaconess Medical Center, Boston, MA, United States, <sup>2</sup>Radiology, Beth Israel Deaconess Medical Center

**Introduction:** Gadobenate dimeglumine (Gd-BOPTA; MultiHance; Bracco Imaging SpA, Milan, Italy) is a recently approved contrast agent with excellent properties for MR angiography (MRA) including a high relaxivity and slow clearance (1). A contrast agent with useful properties for both late gadolinium enhancement (LGE) and MRA is important for specific applications, e.g. for pre- and post-pulmonary vein isolation (PVI) assessment (2,3), for which the MRA is essential to the electrophysiologist for planning the study, and the LGE is now a tool for assessment of potential pre-existing and RF ablation induced scar. However, the current studies suggest that the CNR between the blood and fibrosis—which is essential in imaging left atrial ablation scar or thin endocardial scar, is lower using Gd-BOPTA compared to Gd-DTPA (4,5,6), at both 0.1 and 0.2mmol/kg doses and at multiple times post injection. The purpose of our study was to investigate the blood/fibrosis CNR of Gd-BOPTA LGE vs. Gd-DTPA LGE, to assess their value for imaging scar, especially in the LA. We hypothesize that since the aortic valve and the mitral valve leaflets are fibrotic structures—usually appearing enhanced in high resolution LGE studies—they might be used as a surrogate for thin scar adjacent to blood, permitting comparison of Gd-DTPA and Gd-BOPTA, even in studies without scar.

**Methods:** Seventeen patients with atrial fibrillation, prior to PVI, had 0.2mmol/kg Gd-BOPTA bolus injections for MRA. Fourteen to 50 minutes after injection, the 3D high resolution LGE studies were performed. Eight of these patients were imaged prior or later (usually after PVI) using Gd-DTPA. Blood SNR, blood-valve CNR were measured and valve enhancement was assessed on a 0-2 (2=enhanced, 1= slightly enhanced, 0= not visible) scale by a blinded highly experienced reader. Additionally, 16 unmatched pre-PVI studies with Gd-DTPA were also evaluated for comparison with Gd-BOPTA. Scan parameters for the LGE sequence included 3D inversion recovery GRE, fat-saturation, navigator-gating, 1.3 x 1.3 x 4mm, TR/TE/ flip =5.4ms/2.3ms/25°, 1RR between inversions, with roughly 6 minute scans (2). The relationship between blood-valve CNR and blood-scar CNR was studied in 10 patients post-PVI using the same MR protocol by comparing the brightest valvular and scarred left atrial wall pixels using linear regression.



**Results:** Figure 1 compares a pre-ablation Gd-BOPTA LGE study with a post-ablation Gd-DTPA LGE study. Note that the valves are visible using Gd-DTPA but not Gd-BOPTA. The SNR of scar and valvular pixels and their CNR with blood were highly correlated (SNR: R=0.96, slope=0.8, CNR: R=0.86, slope=0.6). The valves were enhanced in 2/8 (25%) Gd-BOPTA

studies compared to 7/8 (87%) Gd-DTPA studies of the same patients at a different time-points ( $p < 0.02$ ). Most (14/18, 87%) valves were enhanced in the unmatched Gd-DTPA studies. The CNR of the valve was 2.7 vs. 6.6 for Gd-BOPTA and Gd-DTPA, respectively, where the valve was observed. Blood pool SNR was measured to be  $33 \pm 14$  vs.  $17 \pm 9$  ( $p = 0.003$ ) for Gd-BOPTA vs. Gd-DTPA. The valve enhancement score was 0.6 for pre-PVI studies with Gd-BOPTA, and 1.3 in the un-matched Gd-DTPA studies ( $p = 0.01$ ), and 0.6 vs. 1.6 ( $p = 0.02$ ) in the matched studies. Figure 2 shows the relationship between imaging delay post injection and valve enhancement, and compares the Gd-DTPA and Gd-BOPTA studies. For Gd-DTPA, the delays were  $21 \pm 5$ , and  $16 \pm 2$  minutes, for studies with ranking of 2 (enhanced) and 1 (slightly enhanced) respectively ( $p = 0.11$ ). There was no relationship between valve enhancement and time delay for Gd-BOPTA studies (average delay  $31 \pm 11$  minutes). **Conclusions:** Valves are fibrotic, and frequently appear enhanced on high resolution LGE images, with SNR and blood CNR correlated to those of scar—therefore, they serve as a useful surrogate for scar. From this valve enhancement study, we infer that Gd-DTPA LGE acquired with 0.2mmol/kg injection provides improved visualization of any scar abutting blood, such as in the left atrium after PVI, compared to Gd-BOPTA at similar time points and dose. This is likely due to the previously reported lack of a T1 difference between blood and scar using Gd-BOPTA. Longer delays might be superior for visualizing thin scar with Gd-DTPA (Figure 2). 1. Kirchin MA et al. *Invest Radiol.* 1998;33:798–809. 2. Peters DC et al. *JACC Cardiovasc Imaging* 2009; 2:308-316. 3. McGann CJ et al. *J Am Coll Cardiol* 2008; 52:1263-1271. 4. GA. Krombach et al. *Eur Radiol* (2009) 19: 2136–2146 5. Bauner et al. *Invest Radiology* 2008 44:95 6. Schlosser et al. *Radiology* 2005; 236:1041–1046.