

# Apparent diffusion coefficient predicts biochemical response in neuroendocrine liver metastases treated using targeted radiolabelled therapy

D-M. Koh<sup>1</sup>, K. Miyazaki<sup>2</sup>, M. Orton<sup>2</sup>, T. Wallace<sup>1</sup>, D. J. Collins<sup>2</sup>, M. O. Leach<sup>2</sup>, and V. Lewington<sup>3</sup>

<sup>1</sup>Department of Radiology, Royal Marsden NHS Foundation Trust, Sutton, Surrey, United Kingdom, <sup>2</sup>CRUK-EPSRC Cancer Imaging Centre, Institute of Cancer Research, Sutton, Surrey, United Kingdom, <sup>3</sup>Department of Nuclear Medicine, Royal Marsden NHS Foundation Trust, Sutton, Surrey, United Kingdom

**Introduction:** <sup>90</sup>Y-DOTATyr3- octreotide (<sup>90</sup>Y-DOTATOC) therapy targets tumour cells expressing somatostatin receptors and induces tumour apoptosis and necrosis. However, assessment of treatment response using conventional imaging criteria is unreliable because treatment may induce disease stabilization rather than disease regression, and disease can also be slow to regress despite clinical benefits [1]. The apparent diffusion coefficient (ADC) derived by diffusion-weighted MR imaging (DW-MRI) is being evaluated as a biomarker for tumour response to anti-cancer treatment. Tumour ADC is expected to increase as a result of tissue apoptosis or necrosis. However, the value of DW-MRI for assessing the treatment effects of <sup>90</sup>Y-DOTATOC treatment, in patients with neuroendocrine liver metastases is unknown.

**Purpose:** The purpose of this study was to evaluate ADC changes in response <sup>90</sup>Y-DOTATOC treatment after the first cycle of treatment in patients with neuroendocrine (NE) liver metastases.

**Materials and methods:** 18 patients in an ongoing study with NE liver metastases and initially elevated serum chromogranin A levels underwent DW-MRI before and at two months after the first cycle of treatment with <sup>90</sup>Y-DOTATOC administered to a maximum dose of 5GBq per cycle. Intravenous lysine and arginine were infused prior to treatment to minimize renal toxicity and patients received in total two cycles of treatment. MR imaging was performed on a Siemens' Avanto 1.5T MR system using a phase-array body coil. Unenhanced T1 and T2 weighted imaging were performed, followed by free-breathing echo-planar DW-MRI (spin-echo, TR/TE = 4500/60, 380 mm field view, 128 x 128 matrix GRAPPA = 2, section thickness = 6 mm, spectral attenuated inversion recovery fat suppression, bandwidth = 1850Hz, number of excitations = 4, simultaneous gradient application three-scan trace technique) employing 6 b-values (0, 50, 100, 250, 500, 750 s/mm<sup>2</sup>). ADC maps were generated by mono-exponential fit of all b-values images. Regions of interest (ROIs) were drawn by an expert radiologist with more than five years' experience in body DW-MRI on the central three image sections of a randomly selected metastasis more than 2 cm in diameter in each patient. ROIs were drawn just within the inner border of the tumour on the b = 750s/mm<sup>2</sup> image and transferred on to the ADC maps to record their median values. The pre-treatment serum chromogranin A levels and nadir post-treatment levels (mean follow up 12.4 months, range 6 to 18 months) were recorded. The maximum axial diameters of each selected metastasis were also determined before and at 6 months after treatment. We defined tumour response by ADC as a 14% or greater increase in the median ADC value at 2 months after treatment, which is based on previously published measurement reproducibility of the technique (coefficient of repeatability = 14%)[2]. The number of responders versus non-responders according to size measurement, biochemical and ADC criteria were noted. Assuming biochemical response was the 'gold-standard' for response assessment in our study population, the pre- and post-treatment median ADC values of responders versus non-responders were compared using the Mann-Whitney Test. Receiver operating characteristics (ROC) analysis was also performed to determine the diagnostic accuracy of the pre-treatment median ADC values for predicting tumour response.

**Results:** The number of responder versus non-responders according to size measurement, ADC values and serum chromogranin A levels were 4 versus 14, 9 versus 9, and 7 versus 11 respectively. There was excellent agreement in the classification of responders and non-responders using ADC values and serum chromogranin A levels (kappa = 0.78). Using ADC criteria alone incorrectly classified two patients as responders. In one patient, initial ADC increase was observed at 2 months but was followed by ADC reduction at 4 months suggesting tumour progression (**Figure 1**). In the other patient, their disease was stable by size and biochemical criteria for 18 months even though ADC increase was observed. Using biochemical criteria to classify patients into responders and non-responders, we found that responders had significant lower pre-treatment median ADC values [in units of  $\times 10^{-3} \text{ mm}^2/\text{s}$ ] (1.12, 95% CI: 0.89 – 1.34) compared with non-responders (1.40, 95% CI: 1.21 – 1.61) (p = 0.01, Mann-Whitney test) (**Figure 2**). Responders showed a significant increase in the median ADC value (1.76, 95% CI: 1.34 – 2.03) at 2 months after the first cycle of treatment (p = 0.007, Mann-Whitney test). There was no significant change in median ADC value (1.54, 95% CI: 1.36 – 1.68) observed among the non-responders (p = 0.27, Mann-Whitney test) (**Figure 3**). By ROC analysis, a pre-treatment median ADC value of  $\leq 1.32$  had a sensitivity of 85.7% and specificity of 72.7% in identifying responders to <sup>90</sup>Y-DOTATOC treatment.

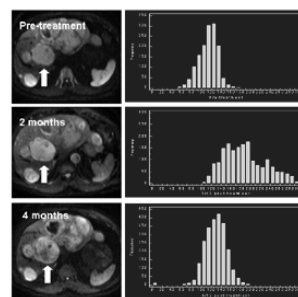
**Discussion:** In patients with neuroendocrine liver metastases, radiolabelled targeted treatment is being investigated as a measure to improve treatment outcomes. However, one of recognized problem is the ability to monitor disease response since effective treatment may not lead to significant reduction in tumour size and biochemical response may also be delayed. Since radiolabelled therapies necessarily incur a radiation burden to the patients, a reliable biomarker of early disease response is urgently needed. As radiolabelled therapies result in direct cell kill and apoptosis, DW-MRI appears well suited as a potential biomarker for response assessment. We found that a lower pre-treatment ADC value of metastases could predict for the likelihood of biochemical response to <sup>90</sup>Y-DOTATOC treatment. This is in line with observations made in brain, colorectal and neck tumours in relation to chemotherapy [3-7]. In our study, responders showed a significant increase in the median ADC values but this was not observed among the non-responders. Furthermore, there was good agreement between disease response defined using ADC criteria versus biochemical criteria. This suggests that ADC measurements could be used to evaluate the early treatments effects of <sup>90</sup>Y-DOTATOC treatment within the first cycle of therapy. Our findings are encouraging but should be validated by larger subsequent studies.

**Conclusions:** The ADC value derived using DW-MRI appears useful for the evaluation of patients with metastatic neuroendocrine tumour to the liver treated using <sup>90</sup>Y-DOTATOC. Increase in the median ADC value of tumours could be observed at the end of the first cycle of <sup>90</sup>Y-DOTATOC treatment among the responders. A lower pre-treatment ADC value also appeared to predict for response to treatment.

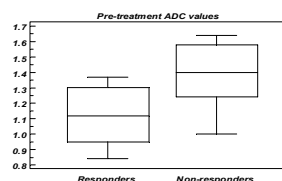
**Clinical implications:** The ADC value shows promise as an early response and prognostic biomarker in neuroendocrine tumours treated by radiolabelled targeted therapy. Further investigations are warranted with the aim of improving patient care.

**References:** [1] Muros MA et al Clin Transla Oncol 2009 [2] Koh DM et al. Eur Radiol 2009 [3] Mardor Y et al. Neoplasia 2004 [4] Cui Y et al. Radiology 2008 [5] Koh DM et al. AJR 2007 [6] Dzik-Jurasz A et al. Lancet 2002 [7] Kim S et al. Clin Can Research 2009

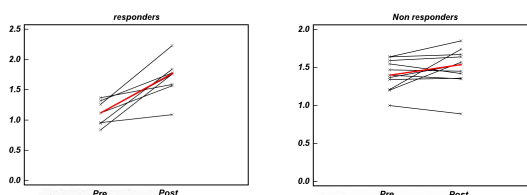
**Acknowledgements:** Supported by the CRUK and EPSRC Cancer Imaging Centre in association with the MRC and Department of Health (England) grant C1060/A10334, also NHS funding to the NIHR Biomedical Research Centre



**Figure 1.** DW-MRI b= 750 s/mm<sup>2</sup> images and voxel ADC histograms of tumour (arrows) before, and at 2 and 4 months after treatment. Note initial increase in median tumour ADC at 2 months, which was followed a reverse histogram shift to the left at 4 months.



**Figure 2.** Box and Whisker plots showing non-responders to treatment having significantly higher initial median ADC values compared with responders (p = 0.01)



**Figure 3.** Ladder plots of the ADC values of responders (left) and non-responders (right) obtained pre- and post-treatment. Cohort median values shown by red lines. A significant increase in the median ADC value was observed in responders but not in non-responders