

Comparison of DWIBS and 18F-FDG PET/CT in newly diagnosed lymphoma

J. Gu¹, Y.-L. Kwong², T. Chan¹, W.-Y. Au², Q. Chan³, J. Zhang^{1,4}, R. Liang², and P.-L. Khong¹

¹Diagnostic Radiology, Queen Mary Hospital, The University of Hong Kong, Hong Kong, China, People's Republic of, ²Medicine, Queen Mary Hospital, The University of Hong Kong, Hong Kong, China, People's Republic of, ³Philips Healthcare, Philips Electronics Hong Kong Limited, Hong Kong, ⁴Memorial Sloan-Kettering Cancer Center, United States

Introduction: Positron emission tomography-computed tomography (PET/CT) is a well established method for the staging of malignant lymphoma, and 18F-fluorodeoxyglucose (18F-FDG) uptake, quantified by standardized uptake value (SUV), is a marker for the level of tumor metabolic activity. Diffusion weighted whole body imaging with background body signal suppression (DWIBS) is an emerging MR technique showing promises in tumor assessment. As cellular density is higher in tumor tissue compared to normal tissue, extracellular space, and thus, free diffusion of water is reduced. Therefore, apparent diffusion coefficient (ADC), a quantitative parameter measured on DWI, maybe regarded as a biomarker for evaluating the cellularity of solid tumors. The aim of this study was to evaluate the diagnostic performance of DWIBS in detection of lymphoma compared with PET/CT, and to assess the correlation between ADC and SUV in lymphoma lesions.

Materials and Methods: 24 consecutive patients with pathologically confirmed newly-diagnosed lymphoma (6 aggressive B cell, 9 indolent B cell, 6 NK/T cell, 3 Hodgkin's lymphoma) who were untreated and having undergone both MRI and PET/CT within a 1 week time frame were included in this study. MR examinations were performed on a 3T scanner (Achieva; Philips Healthcare). Flex-L and Flex-M coils were placed over abdomen and pelvis. Q-body coil was used to cover head and chest. DWIBS was performed in the transversal orientation using the following parameters: TR/TE/TI=7779/48/260 ms; FOV=40×33 cm; matrix=188×159; slice thickness=5 mm; gap=0; b value=0 and 1000 s/mm²; number of acquisitions=4; EPI factor=83; SENSE factor=2. 5 stacks were performed to include coverage from head to the distal thighs. All PET/CT examinations were performed on the same scanner (Discovery VCT, GE Healthcare Bio-Sciences Corp.). A whole body PET scan with a 70-cm axial FOV, 218×218 matrix, 3.27 mm thickness was obtained with five bed positions within 20 minutes. CT images were performed using the following scan parameters: FOV=50cm, matrix=512×512, collimation=0.625 mm×64, pitch=0.984, gantry rotation speed=0.5 second, tube voltage=120 kVp, and tube current=200-400 mA. The CT images were then reconstructed at 2.5mm intervals to fuse with the PET images (Advantage Workstation 4.3; GE Healthcare). The PET/CT and DWIBS images were reviewed by experienced radiologists blinded to the findings of the other imaging modality, and all lesions detected were recorded. ADC map was reconstructed using the standard software on the imaging console (Achieva; Philips Healthcare). ROIs were manually drawn along contours of each lesion on ADC maps on every slice covering the entire lesion. ADCmin is defined as the lowest ADC value among all voxels in each lesion. SUVmax (maximum standardized uptake value) was automatically measured from a 3D ROI which was placed over the entire lesion. ADCmin and SUVmax for the most hypermetabolic lesion per patient were recorded for analysis. Pearson's correlation test was used to detect the relationship between ADCmin and SUVmax. One way ANOVA post hoc test was used to compare the differences of ADCmin and SUVmax between four types of lymphoma (aggressive B-cell, indolent B-cell, NK/T cell and Hodgkin's lymphoma). The findings detected on DWIBS and PET/CT images were compared on a per-lesion basis to determine true-positive (TP), false-negative (FN), and false-positive (FP) rates using PET/CT as the gold-standard.

Results: 115 and 104 lesions were detected on PET/CT and DWIBS respectively. 100 lesions (87.0%) were concordant on PET/CT and DWIBS. 19 lesions were discordant. Of the discordant lesions, 15 lesions were detected on PET/CT but not DWIBS whilst 4 lesions were detected on DWIBS but not PET/CT (Table 1). TP, FN and FP of DWIBS in lymphoma lesion detection were 90.4%, 9.6% and 3.5% (Table 2). ADCmin (mean±S.D.) was $0.39 \pm 0.13 \times 10^{-3} \text{ mm}^2/\text{s}$ in indolent B-cell lymphomas, $0.21 \pm 0.10 \times 10^{-3} \text{ mm}^2/\text{s}$ in aggressive B-cell lymphomas, $0.26 \pm 0.07 \times 10^{-3} \text{ mm}^2/\text{s}$ in NK/T cell lymphomas, and $0.34 \pm 0.15 \times 10^{-3} \text{ mm}^2/\text{s}$ in Hodgkin's lymphoma. SUVmax (mean±S.D.) was 5.4 ± 3.6 in indolent B-cell lymphomas, 12.7 ± 4.8 in aggressive B-cell lymphomas, 8.8 ± 6.6 in NK/T cell lymphomas, and 8.3 ± 4.9 in Hodgkin's lymphoma. There were no overall significant differences of SUVmax and ADCmin between four groups of lymphoma ($p=0.071$), although SUVmax was significantly lower in indolent than in aggressive B-cell lymphoma ($p=0.012$) and ADCmin was significantly higher in indolent than in aggressive B-cell lymphoma ($p=0.024$) (Figure 1). Significant negative correlation was found between SUVmax and ADCmin ($r=-0.575$, $p<0.01$) of indolent B-cell and aggressive B-cell lymphoma (Figure 2).

Conclusion: (1) DWIBS provides satisfactory diagnostic accuracy in lymphoma compared with PET/CT, and with the advantage of no ionizing radiation. Evaluation of T1-weighted and T2-weighted MRI together with DWIBS should improve accuracy. (2) There were significant differences in both ADCmin and SUVmax between aggressive and indolent B-cell lymphoma. ADCmin may therefore be another useful quantitative marker for tumor characterization and classification. (3) Negative correlation was found between ADCmin and SUVmax suggesting an association between tumor cellularity and metabolic activity. **Reference:** (1). Schoder H, et al. J Clin Oncol 2005; 23:4643-4651. (2). Juweid ME, et al. J Clin Oncol 2005; 23:4577-4580. (3). Bohlscheid A, et al. Rofo 2008; 180:302-309.

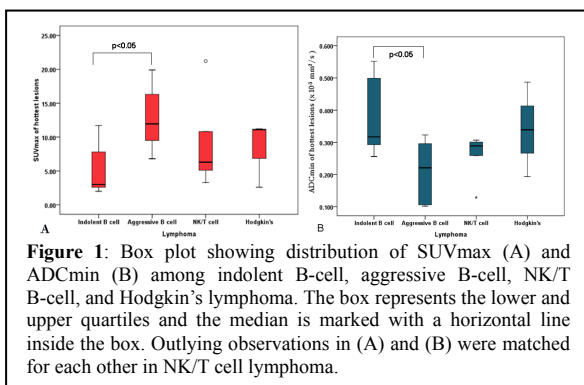


Figure 1: Box plot showing distribution of SUVmax (A) and ADCmin (B) among indolent B-cell, aggressive B-cell, NK/T B-cell, and Hodgkin's lymphoma. The box represents the lower and upper quartiles and the median is marked with a horizontal line inside the box. Outlying observations in (A) and (B) were matched for each other in NK/T cell lymphoma.

Table 2 Qualitative analysis of DWIBS tested against PET/CT

	TP	FN	FP
DWIBS	90.4%	9.4%	3.5%

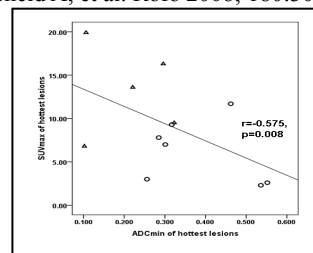


Figure 2: Scatter plot showing the significant negative correlation between ADCmin and SUVmax. Δ=aggressive B-cell lymphomas, ○=indolent B-cell lymphoma.

Table 1 Summary of discordant lesions on PET/CT and DWIBS

Discordant Lesion	n = 19	DWIBS (D) / PET (P) (—)	Size (mm)
Lymph node, cervical	2	D	11.1, 28.9
Lymph node, mediastinal	3	D	10.1, 14.4, 14.7
Brain	1	D	11.6
Nasopharynx	2	D	15.5, 15.8
Lung	1	D	24.9
Kidney	2	D	26.8, 30.9
Bone, T1, T7, L3, rib	4	D	13.0, 18.7, 13.4, 16.8
Lymph node, abdomen and pelvis	3	P	16.5, 18.5, 21.2
Liver	1	P	30.5