

Reduction of Metal Artifacts in Patients with Hip Joint Implants by Using Optimized Imaging Protocols

S. Månsson¹, G. Müller², D. Alamid³, J. Svensson¹, and M. Müller²

¹Medical Radiation Physics, Lund University, Malmö, Sweden, ²Radiology, Lund University, Malmö, Sweden, ³Radiation Physics, University of Gothenburg, Gothenburg, Sweden

Introduction: Metal-on-metal (MOM) hip resurfacing implants were predicted to be suitable for young, active patients (1). However, there are indications that the MOM-implants fail more frequently than traditional implants (2), possibly caused by an aseptic lymphocytic vasculitis-associated lesion in the tissues surrounding the implant (3). The diagnosis of these lesions by MRI would be facilitated by artifact-reducing protocols, which have been outlined recently (3-5). The purpose of this study was to investigate to which extent metal artifacts can be reduced, in the worst case of a stainless steel implant, by optimizing routine imaging protocols, without resorting to special pulse sequences not widely available.

Methods: Images of a patient with a MOM stainless steel implant in the left hip joint were acquired on a 1.5 T scanner with 45 mT/m gradients (Siemens Avanto). An implant of the same kind was embedded in agarose for phantom imaging. Two routine protocols were tested on the phantom: T1w turbo-SE (TR/TE=734/20 ms, ETL=3, slice thick.=5 mm, pixel size=0.6×0.6 mm², bandwidth=200 Hz/pixel, scan time 1:52 min) and T1w STIR (TR/TE/TI=5810/27/180 ms, ETL=7, ST=5 mm, pixel=1.2×1.2 mm², BW=130 Hz/pixel, 3:59 min). For artifact reduction, these protocols were modified (T1w: TR/TE=1380/5 ms, ETL=5, ST=2 mm, pixel=1.0×1.0 mm², BW=765 Hz/pixel, 2:50 min. STIR: TR/TE=4000/7/180 ms, ETL=7, ST=3 mm, pixel=1.1×1.1 mm², BW=765 Hz/pixel, 2:44 min). In the patient, the routine STIR and the two artifact reduction protocols were acquired, and the metal artifact area (defined as the region where anatomical information was missing) was measured by two experienced radiologists.

Results: In the phantom, the extent of the artifacts was reduced in the optimized protocols compared to the routine protocols (Fig. 1). The optimized T1w-protocol (B) resulted in an “on-off” appearance of the artifact (either preserved signal or total signal loss). In the patient, the optimized protocols allowed visualization of structures closer to the implant (Fig. 2). The artifact areas were 40 cm² (artifact reduction T1w), 58 cm² (artifact reduction STIR), and 72 cm² (routine STIR). Variation of the ETL from 1 to 7 had no impact on the image quality of the artifact reduction T1w protocol.

Fig. 1. Phantom images of the MOM hip implant: A) clinical routine T1w, B) artifact reduction T1w, C) clinical routine STIR, and D) artifact reduction STIR. The yellow contour shows the position of the implant (determined by X-ray). The frequency encoding direction is vertical.

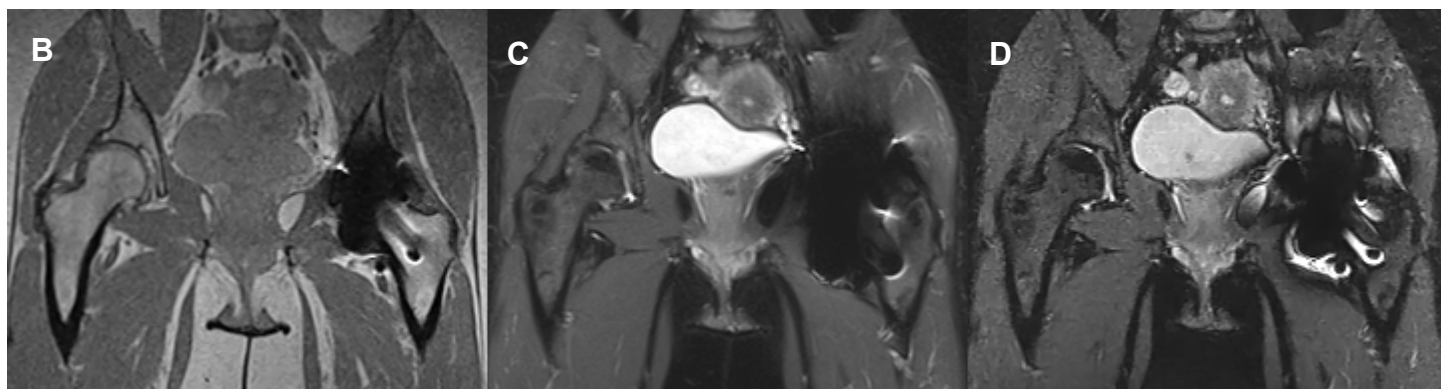
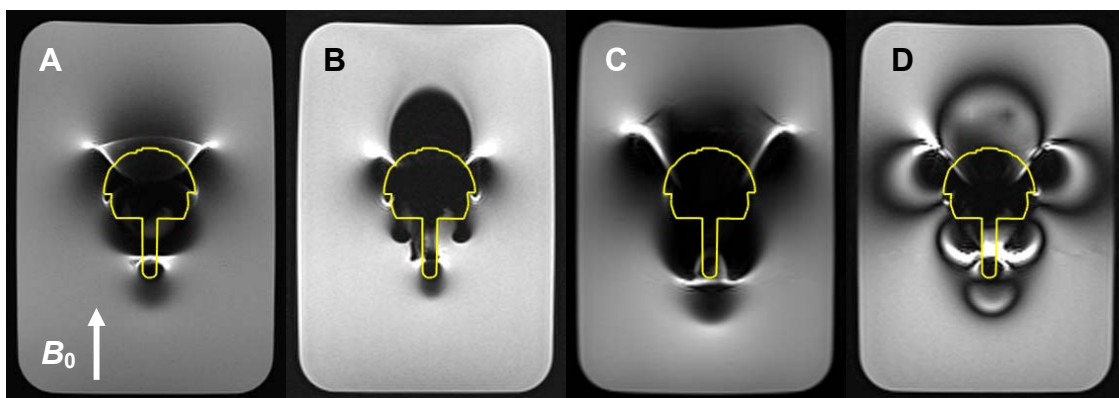


Fig. 2. Images of patient with MOM-implant in the left hip joint: B) artifact reduction T1w, C) clinical routine STIR, and D) artifact reduction STIR.

Discussion and Conclusion: The optimized protocols reduced the artifact size around the implant substantially. The higher spatial resolution and bandwidth compared to the routine protocols lowered the SNR, though. The T1w protocols were superior to the STIR protocols with respect to artifact size. The STIR protocols exhibited, both in phantom and patient, a more complex pattern with dark and bright bands, possibly because the inversion pulse does not coincide with the imaged slice near the implant. Although a direct visualization of the contact area between implant and tissue is still not possible, the improved visibility offered by optimized MRI protocols may be important for detection of prosthetic failure.

References: [1]. Steffen *et al.* J Bone Joint Surg [Br] 2008;90-B:436-41. [2]. National Joint Registry UK. NJR 4th Annual Report 2007. [3]. Hart *et al.* J Bone Joint Surg [Br] 2009;91-B:738-44. [4]. Lee *et al.* RadioGraphics 2007;27:791–803. [5]. Vandevenne *et al.* JBR–BTR, 2007, 90: 345-349.