

# Sequential change of rat cartilage and subchondral bone with experimental osteoarthritis investigated by quantitative T2\* measurements

P-H. Tsai<sup>1</sup>, M-C. Chou<sup>2</sup>, M-H. Lin<sup>3</sup>, C-Y. Lin<sup>3</sup>, H-W. Chung<sup>1</sup>, H-S. Lee<sup>4</sup>, and G-S. Huang<sup>2</sup>

<sup>1</sup>Graduate Institute of Biomedical Electronics and Bioinformatics, National Taiwan University, Taipei, Taiwan, <sup>2</sup>Department of Radiology, Tri-Service General Hospital, National Defense Medical Center, Taipei, Taiwan, <sup>3</sup>Institute of Biomedical Sciences, Academic Sinica, Taipei, Taiwan, <sup>4</sup>Department of Pathology, Tri-Service General Hospital, National Defense Medical Center, Taipei, Taiwan

## Introduction

Osteoarthritis (OA) is a disease related to the degeneration of cartilage, pathological change of subchondral bone (SB) and so force, which may leads to a series of inflammation and pain responses [1]. Several reports have demonstrated that structural changes of knee cartilage, menisci, and SB could be observed in animal models correlated with the severity of OA [2,3]. Recently, quantitative T2 measurement has been a useful method to monitor the progression of OA [4]. In addition, understanding the sequential change of knee joint after tearing of anterior cruciate ligament (ACL) contributes to evaluating OA. As a result, the purpose of this study is to investigate the relationships among cartilage, menisci and SB with the progression of OA by MR T2\* measurements.

## Method

Eighteen Sprague Dawley rats (aged 8-week-old, weighed around 300g) were enrolled in this study and randomly separated into two groups (n=6 for each group). Group 1 was the control group. Group 2 was the experimental group whose right knee was performed with anterior cruciate ligament (ACL) transection for induction of cartilage degeneration at 8 weeks of age. Group 3 was sham group whose skin of the right knee was wounded. At 0, 4<sup>th</sup>, 13<sup>th</sup> and 18<sup>th</sup> week after ACL transection, all the right knees of the rats were imaged in a supine position in a 4.7T MR system (Bruker, Ettlingen, Germany) after being anesthetized with a halothane/oxygen mixture. The proceeding of this study is illustrated in Figure 1. The images were acquired with a quadrature surface coil using a multi-slice multi-echo gradient echo sequence with TR = 2500 ms, TE = 3.5/8.5/13.5/18.5/23.5/28.5/33.5/38.5 ms, slice thickness = 500 μm, matrix size = 256 x 256, in-plane resolution = 117 x 100 μm<sup>2</sup>, NEX = 4, acquisition time = 1h16m48s. The T2\* maps were calculated on a pixel-by-pixel basis by fitting the echo time data and the corresponding signal intensity to a single exponential relaxation model. Regions of interest (ROI) were manually placed on knee cartilages and SB by referencing to the first-echo image to calculate the mean and standard deviation of the T2\* relaxation time (Figure 2). Student t-test was performed to investigate the difference between control and experimental groups on the T2\* values.

## Results

The result of MR T2\* measurements was shown in Table 1. Compared to the control group, the T2\* value of the right knee cartilage in experimental group showed significant differences at 4<sup>th</sup>, 13<sup>th</sup> and 18<sup>th</sup> week after ACL transection (P< 0.01). The significant difference of the menisci T2\* value was shown first at 4<sup>th</sup> week in medial meniscus (posterior horn more significant than anterior horn), and 13<sup>th</sup> week in lateral meniscus respectively (P<0.05). SB was the last one to have significant difference of T2\* value only at 18<sup>th</sup> week (P<0.05). In addition, there is no significant difference between sham group and control group.

## Discussion

The present study indicated the feasibility of quantitative MR T2\* imaging to investigate the sequential change of articular cartilage, menisci and SB with the progression of OA. To our knowledge, this study is the first time to simultaneously assess the structural changes by quantitative MR T2\* measurements. Degeneration of rat menisci shows temporal difference in different locations, which may be connected to the variable mobility related to the biomechanics. Although the anatomical change of SB has been observed at early OA in the previous report [5], significant difference of SB T2\* value was shown at the end point of this study. To sum up, our preliminary finding suggested that the combination of ACL rat model with MR T2\* measurements is useful to evaluate the sequential change of knee joint and the in vivo model has a potential to longitudinally monitor the therapeutic effects of OA.

## Reference

1. Carr AJ. Osteoarthritis Cartilage 1999; 7:230-238
2. Bennett LD, et al. J Rheumatol 2002; 41:917-923
3. Boileau C, et al. Ann Rheum Dis 2008;67:926-932
4. Tsai PH, et al. Osteoarthritis Cartilage 2009 17:988-994
5. Libicher M, et al. Eur Radiol 2005 15:390-394

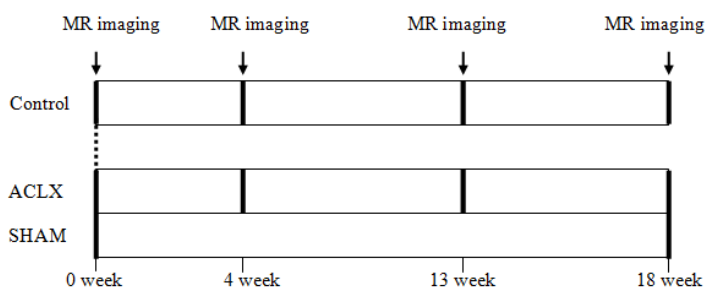
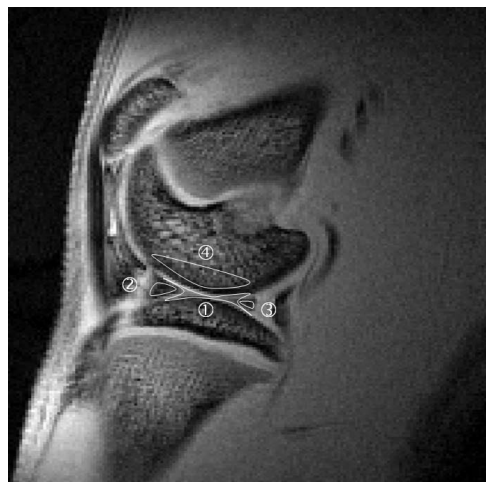

Figure 1 A diagram to represent the proceeding of this study.



T2*(ms)	0 week		4 <sup>th</sup> week		13 <sup>th</sup> week		18 <sup>th</sup> week	
	ACLX	Control	ACLX	Control	ACLX	Control	ACLX	Control
<u>Lateral</u>								
Cartilage	8.77±0.86	8.37±0.29	10.81±0.98 *	8.11±0.24	13.54±1.41 *	8.22±0.30	14.49±1.79 *	8.17±0.36
Ant_meniscus	5.58±0.60	5.60±0.69	5.87±0.67	5.31±0.22	7.37±0.54 *	5.61±0.59	7.49±0.69 *	5.74±0.41
Pos_meniscus	5.94±0.36	5.92±0.41	6.79±0.77	6.05±0.72	7.41±0.48 *	5.60±0.28	7.62±0.49 *	5.89±0.45
SB	6.52±0.32	6.51±0.27	6.27±0.46	6.41±0.48	7.35±0.80	6.64±0.73	7.61±0.61 *	6.31±0.27
<u>Medial</u>								
Cartilage	8.77±0.52	8.42±0.31	10.85±0.70 *	8.17±0.47	13.41±1.91 *	8.16±0.36	14.57±1.13 *	8.14±0.47
Ant_meniscus	5.72±0.67	5.89±0.25	6.72±0.87 *	5.60±0.32	7.13±0.63 *	5.82±0.29	7.88±0.49 *	5.66±0.36
Pos_meniscus	5.98±0.35	5.80±0.73	7.01±0.33 *	5.64±0.73	7.34±0.43 *	5.78±0.51	7.94±0.58 *	5.74±0.33
SB	6.51±0.48	6.30±0.31	6.53±0.58	6.65±0.42	7.34±0.68	6.77±0.73	7.98±0.49 *	6.50±0.46

Table 1 The result of T2\* (mean ± SD) values measured at 0, 4<sup>th</sup>, 13<sup>th</sup> and 18<sup>th</sup> week.