

## Multi-component T2\* relaxation of knee cartilage under UTE acquisitions

Y. Qian<sup>1</sup>, A. A. Williams<sup>2</sup>, C. R. Chu<sup>2</sup>, and F. E. Boada<sup>1</sup>

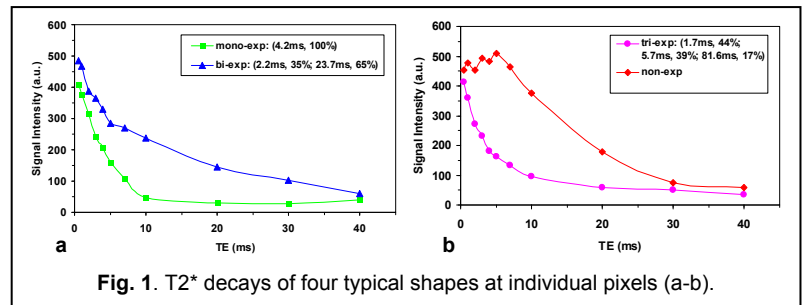
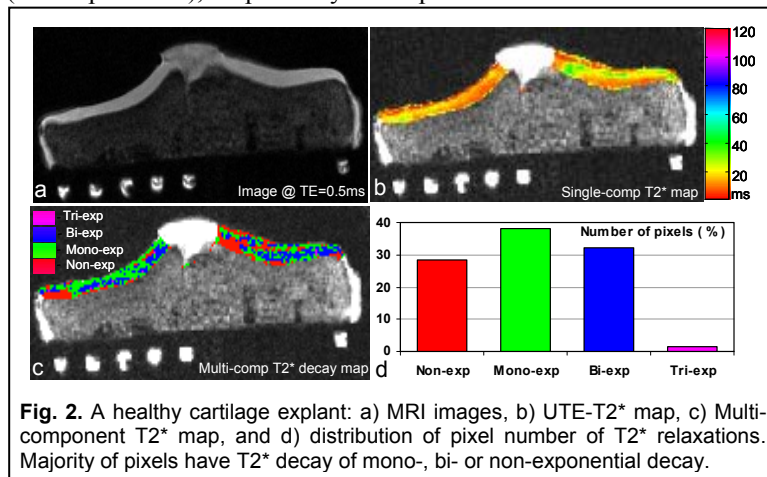
<sup>1</sup>MR Research Center, Radiology, University of Pittsburgh, Pittsburgh, PA, United States, <sup>2</sup>Orthopaedic Surgery, University of Pittsburgh, Pittsburgh, PA, United States

**INTRODUCTION** This work reports observations of T2\* relaxation in human knee cartilage explants under ultrashort echo time (UTE) acquisitions in vitro. The objective of this study was to determine the number and distribution of T2\* components. We hypothesize that the three major constituents of articular cartilage extracellular matrix (water, collagen, and proteoglycan) contribute to the existence of multiple T2\* relaxations in the tissue. Previous nuclear magnetic resonance (NMR) relaxation studies on bovine knee cartilage plugs suggest that there are four proton spin reservoirs of distinct T2 relaxations: bulk water (T2~20ms), collagen (T2~0.02ms), PG (T2~1ms), and water trapped within collagen fibrils (T2~4ms) (1). However, there are no similar studies on human cartilage on clinical MRI scanner reported in literature. This study was intended to fill this gap of knowledge.

**EXPERIMENTS** Experiments were performed on a whole-body 3T MRI scanner (Magnetom Trio Tim, Siemens Medical Solutions, Erlangen, Germany) with an 8-channel knee coil (Invivo Inc., Gainesville, FL, USA). Six tibial plateau explants harvested from human intact cadaveric knees (age 58±28yrs in a range of 18-82yrs, 3 males and 3 females, 3 healthy and 3 advanced OA) were scanned under the institutional CORID- and IRB-approved protocols. Data acquisitions were implemented using a home-developed 3D UTE sequence (acquisition-weighted stack of spirals, AWSOS) (2), with parameters of hard RF pulse of 0.4ms, TR=100ms, TE=0.5-40ms at 11 steps,  $\theta=30^\circ$ , total scan time=4.3-5.3min for one TE image, FOV=100mm, matrix size=256, spatial resolution=0.391mm, slices=40-50 at a thickness of 2mm, in-plane spirals=64 at readout time Ts=5.28ms, fat saturation on. Manual shimming was used to achieve good shim (linewidth <20Hz). No corrections were used during gridding-based spiral image reconstruction. The non-negative least-squares (NNLS) algorithm was used for multi-component T2\* fitting for each of pixels. An extra large T2\* value of 350ms was included in the fitting to count on base-line signal. An interactive iteration was implemented under a condition of minimum number of T2\* components and the NNLS fitting was performed in MATLAB (R2009a, The MathWorks, Inc., Natick, MA).

**RESULTS** Based on the UTE images of the cartilage explants, four types of T2\* decays were detected (Fig. 1): mono-, bi-, tri-, and non-exponential decay. The “non-exponential” decay appeared to consist of a delayed T2\* decay with a flat segment at short TEs. The majority of the cartilage pixels (~99%) were found to have T2\* decay of mono-, bi-, or non-exponential, with an average long-T2\* of ~30ms and short-T2\* of ~4ms. Figure 2 demonstrates the number and spatial distributions of the four T2\* decay types in a healthy cartilage explant (age 18yr), as well as the corresponding UTE-T2\* map. The UTE-T2\* map (Fig. 2b) was calculated based on a single-component T2\* decay model using all the data acquired at 11-TEs including an ultrashort echo time (UTE) of 0.5ms (Fig. 2a). The multi-component T2\* map illustrates the spatial distribution of T2\* relaxations (Fig. 2c).

**DISCUSSION** The observed T2\* decays are attributed to bulk water (~30ms), collagen-trapped water (~4ms), and PG depletion (non-exponential), respectively. We speculate that the more rare tri-exponential decay (~1%, T2\*~1ms) is due to fragmented PG macromolecules. In light of these observations, we conclude that a two-component model is sufficient to describe T2\* decays in human knee cartilage (3T scanner and min TE=0.5ms). Our findings suggest that bi-exponential T2\* decay may be indicative of structurally normal cartilage regions while the mono-exponential T2\* decay may be a reflection of relative loosening of local cartilage networks and hence a sign of early cartilage degeneration. Further studies are needed to elucidate the basis of multiple component T2\* decay in articular cartilage.



**REFERENCES** [1] Lattanzio PJ, etc. MRM 2000; 44:840-851. [2] Qian Y, etc. MRM 2008; 60:135-145.