

# Longitudinal analysis of articular cartilage for microfracture and mosaicplasty procedures using quantitative T1rho and T2 MRI

W. W. Schairer<sup>1</sup>, A. A. Theologis<sup>1</sup>, S. Majumdar<sup>1</sup>, X. Li<sup>1</sup>, and B. Ma<sup>1</sup>  
<sup>1</sup>University of California, San Francisco, San Francisco, CA, United States

## Purpose

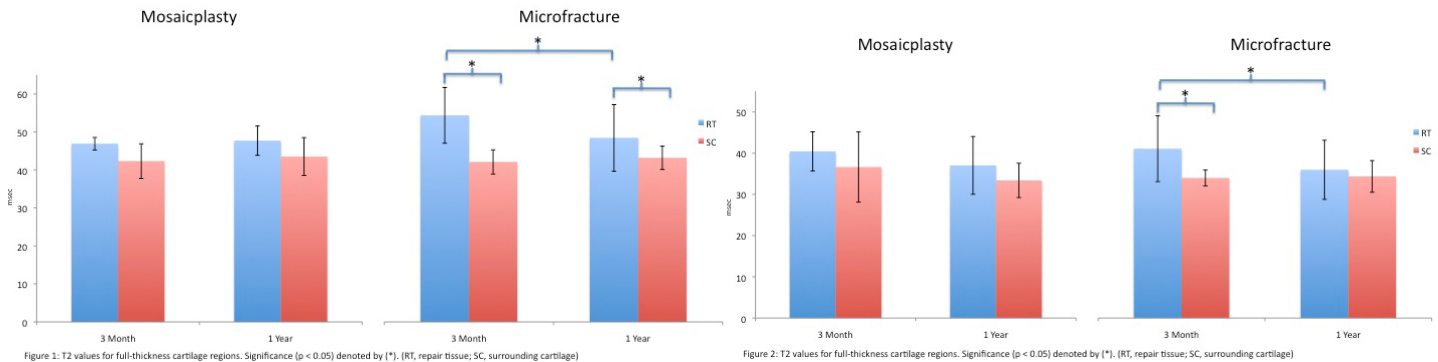
To evaluate the longitudinal changes of the articular cartilage of the knee after treatment of focal cartilage defects with either mosaicplasty or microfracture surgeries. The hypothesis is that mosaicplasty, which transplants normal articular cartilage from a non-weight bearing portion of the femur, will have better T1rho and T2 characteristics than microfracture, which generates fibrocartilage.

## Materials and Methods

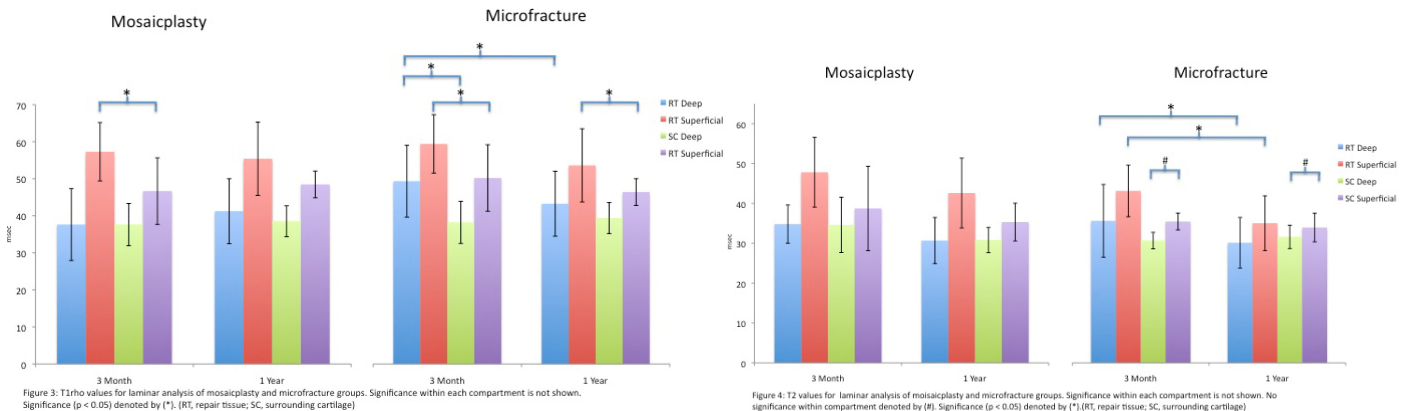
A total of 14 patients suffering from focal cartilage defects of the femur were enrolled in the study. Five patients received mosaicplasty (MOS) surgery and nine patients received microfracture (MFX) surgery to repair the damaged cartilage. Each patient was studied at 3-months and 1-year post-operatively with a 3.0-Tesla MRI system and received SPGR, T1rho, and T2 scans. Articular cartilage regions were defined on the SPGR image using an spline-based in-house MATLAB program. Repaired cartilage locations were verified by surgical report. Transfer of these splines to T1rho and T2 maps allowed quantification of surgical site and surrounding cartilage. Repaired tissue (RT) and surrounding cartilage (SC) regions were also investigated with a laminar analysis, which involved dividing each region into superficial (more distal to cortical bone) and deep (more proximal to cortical bone) regions. Analysis was performed with a paired t-test with significance being defined as a p-value < 0.05.

## Results

Full-thickness T1rho and T2 analysis found no significant differences between repaired tissue and normal tissue for the mosaicplasty group. The microfracture group showed significant differences between repair and normal cartilage, except for the T2 values at 1-year. Also, the repair tissue showed significant changes between 3-months and 1-year for both T1rho and T2 measures.



Laminar analysis of T1rho data showed significant differences between deep and superficial cartilage within each region, for both groups at all timepoints. The same trend was found in the laminar analysis of T2 data, except the surrounding cartilage region for the microfracture group, where deep and superficial cartilage were not significantly different at 3-months or 1-year. Additionally, significant changes in T2 were found in the repair tissue for both the deep and superficial cartilage between 3-months and 1-year for the microfracture group. Significant changes were also found in T1rho for the deep repair tissue from 3-months to 1-year.



## Conclusion

Quantitative MRI is a noninvasive method to investigate the cartilage following traumatic events such as surgery. T1rho measurements indicate changes in the extracellular matrix, such as loss of collagen and proteoglycan. T2 measurements are sensitive to water content and collagen integrity. Our results show that mosaicplasty results in cartilage that is more similar to surrounding cartilage, while microfracture tends to result in cartilage that is significantly different compared to surrounding cartilage. While T1rho and T2 signals are initially raised with both mosaicplasty and microfracture procedures, these measures are significantly decreased in the microfracture group from 3-months to 1-year, indicating changes in the cartilage content and perhaps faster healing in the microfracture group compared to the mosaicplasty group. These results do not support the hypothesis, and thus more long-term data is needed for further comparison of mosaicplasty and microfracture procedures.