

Perfusion abnormalities of bone marrow edema-like lesions in knees with anterior cruciate ligament injury using dynamic contrast-enhanced MRI

J. Zuo¹, S. Majumdar¹, and X. Li¹

¹Radiology and Biomedical Imaging, Univ. of California, San Francisco, San Francisco, CA, United States

Introduction

Anterior cruciate ligament (ACL) tear is a common knee injury, and is a risk factor of post-traumatic osteoarthritis (OA) [1]. The disease is frequently associated with bone marrow edema-like (BMEL) lesions which exhibit as an area of high signal intensity in T2-weighted, fat-saturated fast spin echo MR images. BMEL is also commonly seen in OA and has been associated with disease progression and pain in OA [2]. However, the knowledge on the pathophysiology and significance of BMEL in ACL-injured knees is very limited. Dynamic contrast enhanced MRI (DCE-MRI) can probe bone marrow and subchondral bone perfusion and fluid dynamics. Impaired perfusion in bone may lead to cartilage degeneration. A recent study showed bone marrow abnormalities were associated with BME in OA [3]. The aim of this study is to apply DCE MRI to evaluate bone marrow perfusion in patients with ACL tears, and to compare the perfusion patterns between BMEL region and normal appearing bone marrow region.

Method

MR images were acquired on a GE 3T MR scanner (General Electric Medical Systems, WI) with a quadrature knee coil. Seven subjects were studied: 5 patients had acute ACL injury and were scanned within 4 weeks post injury and prior to ACL reconstruction, one patient had chronic non-operative ACL tear (3 year post injury) and 1 healthy control. The imaging protocols included sagittal FSE T2-weighted images with fat saturation for evaluating BMEL (TR/TE = 3700/43ms, resolution = 0.3 * 0.3 * 2.5 mm). For DCE-MRI, a bolus of 0.1 mmol/kg body weight (single dose) Gd-DTPA was rapidly administered via a 20-gauge intravenous catheter with a constant rate of 2mL/per second by a power injector. T1-weighted SPGR sequences were scanned before and during contrast agent administration (TR/TE = 8/3ms, resolution = 0.8 * 0.8 * 3 mm, temporal resolution = 10s, time points =50). BME was segmented from T2-weighted FSE images using a thresholding algorithm that was developed previously [4]. Signal intensity changes of BMEL to normal bone marrow were calculated. Three perfusion parameters were obtained based on the signal-time curve obtained from DCE-MRI: peak time, peak value (normalized to baseline signal intensity) and slope of the enhancement were quantified for each pixel [5]. The region of interest (ROI) of BME was defined in T2-FSE images and was later overlaid to the perfusion map after registration. The average parameter was calculated within BMEL and within normal bone marrow (NBM, drawn in the same compartment where BMEL was defined) for each patient. Student paired t-test was employed to study statistical significance (P < 0.05).

Results

Six BMELs were found in 5 patients (3 in lateral femoral condyle, 3 in later tibia) with acute ACL injuries. No BMELs were found at 1-year follow up. No BMELs were found in the patient with chronic ACL tear and in healthy controls. Figure 1a shows T2-FSE images for a ACL-injured knee with BME in lateral femoral condyle (red ROI) and NBM (blue ROI) in the same compartment; Representative time signal intensity curves (normalized to baseline signal) from BMEL (red ROI) and normal bone marrow in acute ACL-injured knee (blue ROI), normal appearing bone marrow in non-operative chronic ACL-injured knee and control knee are plotted in Fig1b. The normalized signal intensity in the BMEL showed a significant increase compared with NBM, chronic ACL and control subjects. Statistical analysis indicated there were significant difference between BMEL and NBM for peak value (P=0.003) and slope (P=0.015). No significant differences (P=0.09) were found for peak time between the two groups (Fig. 1c).

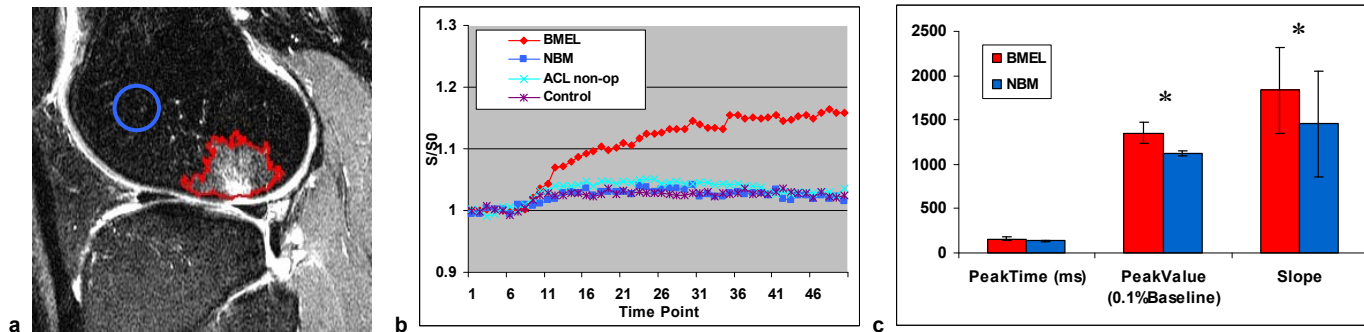


Fig1. a. BMEL ROI (in red) and NBM ROI (in blue) were defined on a T2-weighted FSE image. b. Normalized time intensity curve from different ROIs. c. Significant differences (indicated with *) were found in the peak value and the slope of the DCE curves between BMEL and NBM groups.

Discussion

BMEL lesion was evaluated with DCE MRI in this study and depicted significant different intensity curve compared with normal appearing bone marrow. Peak value and slope that were derived from the DCE curves indicated significant differences between these two groups, suggesting that these two parameters may be useful biomarkers for the early diagnosis of bone perfusion abnormality. The subchondral region is highly vascularized and accounts for providing nutrition to cartilage. Pathology in subchondral bone, therefore, may lead to or speed up the deterioration of the overlying cartilage. Quantifying perfusion parameters within bone marrow and subchondral bone in acutely-injured knees may identify risk factors for post-traumatic OA development in such knees. We will follow these patients up using DCE-MRI and compare the perfusion findings with BMEL in OA knees.

Acknowledgements NIH K25 AR053633 and UCSF REAC funds.

- References**
- [1] Lohmander et al, Arthritis Rheum 2004; 50:3145-3152.
 - [2] Felson et al, Ann Intern Med 2003; 139:330-336.
 - [3] Aaron et al, Ann NY Acad Sci 2007; 1117:124- 137.
 - [4] Li X et al, J Magn Reson Imaging 2008; 28:453-461
 - [5] Noworolski et al, Mag Reson Med 2005; 53:249- 255.