

# Correlation of Atherosclerotic Plaque Compositions in Coronary and Carotid Arteries

Q. Zhao<sup>1</sup>, X. Zhao<sup>2</sup>, J. Cai<sup>3</sup>, F. Li<sup>2</sup>, J. Yang<sup>1</sup>, C. Yuan<sup>2</sup>, and Z. Cai<sup>3</sup>

<sup>1</sup>Radiology, The general hospital of Beijing military area command of People's liberation army, Beijing, China, People's Republic of, <sup>2</sup>Radiology, University of Washington, Seattle, United States, <sup>3</sup>Radiology, The general hospital of chinese PLA, Beijing, China, People's Republic of

## Introduction:

Atherosclerosis has been shown to be a systematic disease which often involves multiple vascular beds, such as coronary and carotid arteries [1]. The size of carotid lipid-rich necrotic core (LRNC) and presence of intraplaque hemorrhage (IPH) were demonstrated to be high risk features due to their correlations with neurovascular events [2,3]. For coronary atherosclerosis, previous studies suggest that coronary mixed type of atherosclerotic plaques may be vulnerable lesions prone to developing cardiac events [4]. These studies indicate that the assessment of plaque compositional features in both coronary and carotid arteries is necessary. Recently, a number of studies demonstrated a significant correlation between coronary and carotid atherosclerosis [5]. However, the association of coronary and carotid plaque compositions is unknown.

**Purpose:** This study sought to determine the correlation of atherosclerotic plaque compositions between coronary and carotid arteries using CT and MRI.

**Methods:** One hundred and twenty-three subjects (mean age 58 years, 96 males) with suspected coronary artery disease underwent coronary CT angiography (CTA) on a Siemens Dual Source CT and carotid MR imaging on a GE 3.0T MR scanner within 2 weeks interval. Coronary CTA imaging parameters were as follows: 64×0.6 mm, 0.33s/rot, 120 kV, 350 mAs, pitch 0.20-0.28, reconstructed image slice thickness 0.75mm with 0.5mm slice spacing on 60-80% RR interval. Contrast media (Iomeprol 370mg I/ml, Bracco) was injected intravenously with bolus of 70ml at 5 ml/s. A standardized multi-contrast protocol [6] was used to perform carotid MR imaging with the following parameters: T1w, quadruple inversion-recovery, TR/TE 800/8.8ms; Double IR, TR/TE 3000/13.1ms for PDw and 3000/56.9 ms for T2w; and 3D TOF: TR/TE 29/2.1ms, flip angle 20°. MR images were acquired with 2 mm slice thickness, field of view of 14 cm, and matrix size 256×256. Coronary plaques were classified into three types: non-calcified, calcified, and mixed type plaques [7]. The presence/absence of plaques and plaque scores (plaque number) for three types of plaques were evaluated for each subject. Presence/absence and the volume of calcification (CA), LRNC and IPH were identified and measured by two trained reviewers with consensus blinded to coronary CT images using a custom designed software (CASCADE [8], Seattle, WA, USA). The three types of coronary plaque scores in patients with and without carotid CA, LRNC, and IPH were compared. The Volumes of carotid CA, LRNC, and IPH in subjects with and without coronary non-calcified, calcified, and mixed type plaques were also compared. ROC analysis was used to determine the AUC of coronary plaque scores for classifying presence of carotid CA, LRNC, and IPH. In addition, the AUC of carotid CA, LRNC, and IPH volume for classifying coronary different type of plaque were also analyzed.

**Results:** Subjects with carotid CA or LRNC showed significantly larger coronary three types of plaque scores than those without carotid plaque compositions (Table 1). Significant difference can be found for coronary mixed type plaque score only in subjects with and without carotid IPH (Table 1). For subjects with

and without coronary non-calcified plaques, there was no significant difference for all carotid compositions volumes (Table 2). Significant differences were found for CA and LRNC volumes but not for IPH volume in Subjects with and

without coronary mixed type or calcified plaques (Table 2). ROC analysis revealed that coronary calcified plaque score was a stronger classifier of carotid CA than other type of coronary plaque scores (Table 1). In classifying carotid IPH, coronary mixed type plaque score was stronger classifier than other coronary plaque scores (Table 1). Compared to carotid IPH volume, both carotid LRNC and CA volumes were stronger classifiers of coronary mixed type and calcified plaques (Table 2).

**Discussion:** This study investigated the correlation between coronary and carotid atherosclerotic plaque compositions. We found that coronary mixed type plaques were effective classifiers of all carotid plaque compositions, especially for IPH (Fig. 1). In addition, our results showed that coronary calcification was significantly correlated with and carotid calcification and LRNC. This finding suggests that coronary calcification may be an indicator for carotid LRNC and calcification,

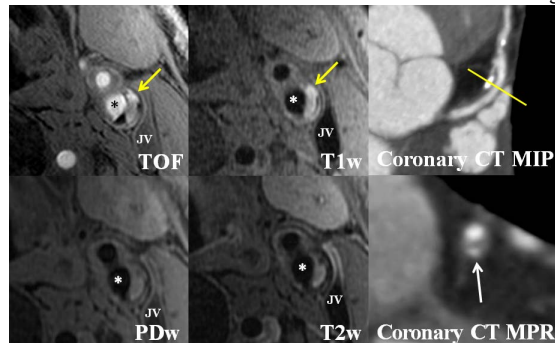


Fig. 1: Hyperintense of IPH (yellow arrow) on TOF and T1w images was found in left internal carotid artery (star). A mixed type plaque can be observed in the same patient on proximal left anterior descending coronary artery (white arrow) on CT images. The MPR image was reformatted from the location (yellow line) on MIP image.

particularly for the latter. Of carotid plaque compositions, we found that carotid calcification volume were effective classifiers of coronary mixed type and calcified plaques. In addition, carotid LRNC volume was found to be an effective classifier of coronary mixed type plaque.

**Conclusions:** coronary atherosclerotic plaque compositions are significantly associated with carotid atherosclerotic compositional features. In particular, coronary mixed type plaques may be effective classifiers of the presence of all carotid plaque compositions, especially for carotid IPH. The strong correlation of calcification between coronary and carotid arteries suggests that, in these two vascular beds, calcification in one vasculature can be an indicator for another vasculature. In addition, the size of carotid LRNC and calcification may be an effective classifier of coronary mixed type plaques.

## References:

- [1] CAPRIE Steering Committee. Lancet. 1996;348:1329-1339.
- [2] Davies MJ et al. Br Heart J. 1993;69:377-381.
- [3] Cappendijk VC et al. J Magn Reson Imaging. 2008;27:1356-1361.
- [4] Sarno G et al. EuroIntervention. 2008;4(3):318-323.
- [5] Taylor AJ et al. Atherosclerosis. 2008;197:339-345.
- [6] Yarnykh VL et al.
- [7] Lin F et al. Atherosclerosis. 2008 Apr;197:700-9.
- [8] JMRL. 2006;23:691-8.
- [9] Kerwin W et al. Top MRI. 2007;18:371-8