

# Integrating high spatial-resolution, 3D whole-heart viability imaging and coronary MRA at 3Tesla

Q. Yang<sup>1</sup>, K. Li<sup>1</sup>, X. Bi<sup>2</sup>, J. An<sup>3</sup>, H. Ma<sup>1</sup>, F. Huang<sup>4</sup>, R. Jerecic<sup>3</sup>, and D. Li<sup>5</sup>

<sup>1</sup>Radiology, Xuanwu Hospital, Capital Medical University, Beijing, Beijing, China, People's Republic of, <sup>2</sup>Siemens Medical Solutions, <sup>3</sup>Siemens Healthcare, MR Collaboration NE Asia, <sup>4</sup>In vivo Corporation, <sup>5</sup>Radiology, Northwestern University

**Introduction:** Previous contrast-enhanced whole-heart coronary MRA (CMRA) studies at 3.0T have shown high sensitivity and moderate specificity for the detection of stenosis in patients suspected of coronary artery disease (CAD). However, a major advantage of 3.0T contrast-enhanced CMRA is the potential to combine lumenographic information and associated myocardial viability in the same setting. The feasibility of integrating high spatial-resolution, 3D whole-heart viability imaging and coronary MRA at 3 Tesla has been evaluated in volunteer studies. No clinical results using this technique at 3T were available so far.

**Purpose:** To evaluate whether contrast-enhanced whole-heart coronary MRA can characterize myocardial infarct (MI) with patterns similar to those obtained by conventional 2D MR technique. The diagnostic accuracy of contrast enhanced 3T whole-heart CMRA were also evaluated in consecutive patients with suspected CAD using conventional x-ray coronary angiography (CAG) as reference standard.

**Methods and Materials:** 50 patients with suspected coronary artery disease who were scheduled for coronary angiography (CAG) underwent CMRA at 3T (MAGNETOM Tim Trio, Siemens) after informed consent was obtained. A 32-channel receiver coil was used for data acquisition (In vivo, Gainesville, FL). For image acquisition an ECG-triggered, navigator-gated, inversion-recovery prepared, segmented gradient-echo sequence was used with an acceleration factor of three in the phase-encoding direction using GRAPPA reconstruction. Imaging parameters included: voxel size 0.55x0.55x0.65 mm<sup>3</sup> (interpolated from 1.1x1.1x1.3 mm<sup>3</sup>), TR/TE = 3.3/1.5 msec, flip angle = 20°, bandwidth = 700 Hz/pixel, TI=200 msec. Contrast agent (0.15 mmol/kg body weight, MultiHance, Bracco, Italy) was intravenously administered at a rate of 0.3 ml/sec. For comparison, reference standard 2D segmented, breath-hold phase-sensitive inversion-recovery DE-CMR infarction imaging was performed in the 4-chamber, 2-chamber and multiple short-axis views. Imaging parameters for 2D imaging included: 1.9 × 1.9 × 8.0 mm<sup>3</sup>, voxel size, TI = 300 msec, TR/TE = 8.4/3.4 msec, bandwidth = 140 Hz/pixel. For MI image analysis, standard 17-segment AHA classification system was used. The diagnostic accuracy in detecting significant stenoses (≥50% of vessel lumen) was evaluated on the assessable segments only, as well as on all segments. Both non-assessable segments and the segments of the patients where the scan failed were considered to have a stenosis.

**Results:** Whole-heart MRCA was successfully completed in 46 of 50 (92%) patients. The averaged imaging time was 6.9± 1.8 min. MI was observed in 12 of 46 patients by 2D PSIR. Whole-heart MRCA correctly detected the MI in all the 12 patients and correctly ruled out MI in 34 patients. The MI regions measured by Whole-heart MRCA and 2D PSIR were highly correlated (r=0.89, P<0.01). Example images are shown in Fig 1 and 2.

**Conclusion:** The study demonstrates that it is feasible to integrate whole-heart coronary MRA and viability imaging clinically. The information on tissue characterization it provides can be obtained almost for free when Whole-heart MRCA is performed for the purpose of coronary imaging. Coronary MRA yields information of the diseased vessels and can potentially supplement the information acquired from viability imaging.

**Reference:** 1. Yang Q, et al. J Am Coll Cardiol, 54: 69-76, 2009. 2. Bi X, Li D, et al. Proceedings of 15th annual ISMRM, Toronto.

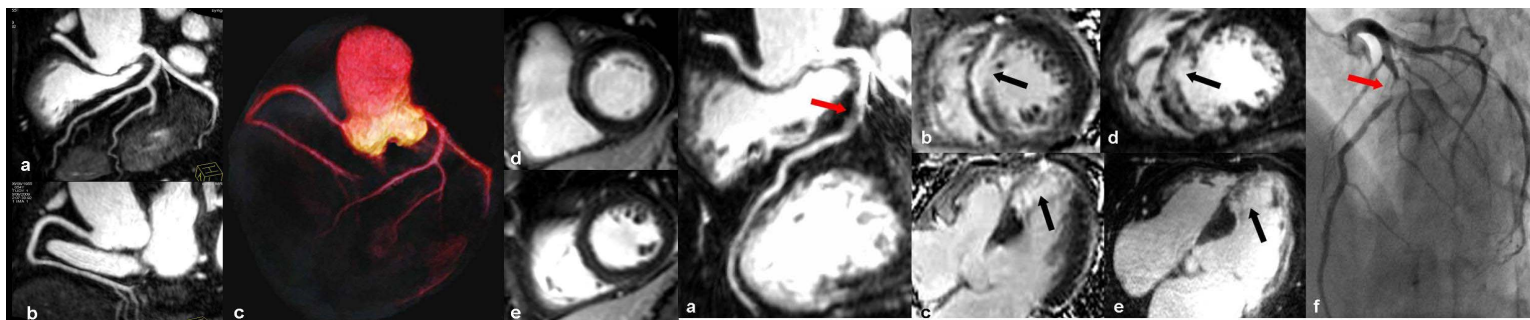


Fig 1: 3T whole-heart coronary MR images of a 54 year-old patient acquired with 32-channel cardiac coils. Reformatted whole-heart coronary artery images (a,b) and viability images (d,e) demonstrate normal vessel and myocardium. Long segments of all major coronary arteries and normal myocardium can be clearly visualized on VR image (c)

Fig. 2: 3T whole-heart coronary MR images of a 69 year-old patient. Reformatted image (a) detects a significant LAD stenosis (red arrow) correlation with CAG (f). Reformatted image (d,e) shows MI (black arrow) correlated well with 2D PSIR images (c,d)