

Hepatic MR Imaging for Differentiation of Biopsy-Proven Steatosis, Iron Deposition, and Combined Disease: One-Dimensional In / Opposed Phase Analysis vs. Two-Dimensional Computer-aided Dixon Discrimination

M. R. Bashir¹, E. M. Merkle¹, and D. T. Boll¹
¹Radiology, Duke University Medical Center, Durham, NC, United States

Summary

Steatosis hepatis functions as an inducer of hepatic iron metabolism dysregulation. MR two-point Dixon T1w imaging with subsequent comprehensive four-phase decomposition analysis facilitated not only metabolite decomposition of intrahepatic lipids and iron ions in steatosis hepatis and hepatic iron overload, but also allowed decomposition of metabolites in combined disease in an in-vivo patient population employing manual as well as computer-aided two-dimensional metabolite discrimination algorithms, with liver biopsy functioning as reference standard.

Introduction

The metabolites most commonly associated with diffuse liver disease are triglycerides and iron ions. Its sensitivity for identifying these hepatic metabolites non-invasively, uniquely suits abdominal MRI with dual-echo imaging sequences for characterization of diffuse liver disease by exploiting chemical shift phenomena as well as pronounced T2*-effects. Implementation of clinical Dixon MR imaging allows near-simultaneous acquisition of in- and opposed-phase MR data series and, additionally, in concert with two-point Dixon processing, yields 'water-vector' and 'fat-vector' data series; each voxel is subsequently characterized by four intensity parameters.

Recent discoveries in assessing hepatic fat and iron metabolism pathways, however, showed that regulation mechanisms essential for systemic fat and iron uptake converged in the liver in a mutual-dependent fashion: steatosis hepatis functions as an inducer of iron metabolism dysregulation. Decomposition of underlying intrahepatocellular lipid and iron storage in combined disease, however, may be complicated by non-differentiable simultaneous signal loss on in-phase as well as opposed-phase MR imaging due to simultaneous competing T2*-effects and chemical shift phenomena [1-3].

This study was designed to test the hypothesis that clinical MR two-point Dixon T1w imaging with subsequent comprehensive four-phase decomposition analysis will enhance diagnostic accuracy to characterize steatosis hepatis, hepatic iron overload and combined disease beyond the capabilities of dual-echo MR acquisition alone in an in-vivo patient population with liver biopsy functioning as reference standard [4].

Methods

IRB approval was obtained. Sixty patients (25 male, 35 female) who had undergone recent random core liver biopsy and had received hepatic MR examinations within a mean interval of 31.8±40.8 days, were included. Seventy-five hepatic MR examinations with T1w two-point Dixon techniques were performed on 1.5 T (n=62, Magnetom Avanto – a TIM system) and on 3 T (n=13, Magnetom Trio – a TIM system, Siemens, Erlangen, Germany) MR scanners. In- and opposed-phase Volumetric Interpolated Breath-hold Examination (VIBE) sequences using TR / TE_{opposed-phase} / TE_{in-phase} of 7.48 (3.91) / 2.38 (1.23) / 4.76 (2.45) ms, on 1.5 T and (3 T), respectively, were acquired. Water- and fat-decomposition was achieved by Dixon-based raw-data calculation algorithms. Five hepatic regions of interest were manually selected and mirrored onto each of the four image series. Regions of interest were ~3 cm² in size and avoided vessels, lesions, and artifacts. Paired I/O and F/W ratios were calculated (4).

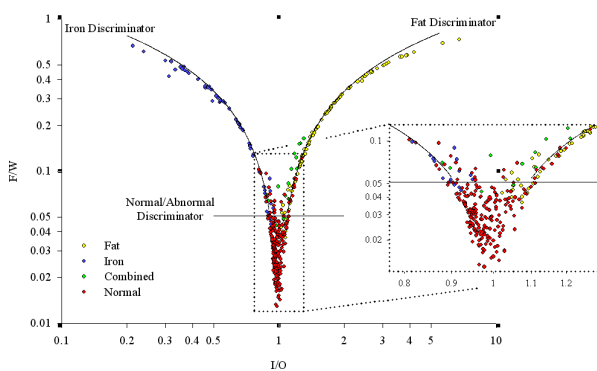


Figure 2 – Shows differentiation of normal liver and all three disease states using the two-dimensional analysis.

Results

Discrimination characteristics are shown below. Overall, the manual two-dimensional technique was as accurate as the one-dimensional technique for detecting of steatosis hepatis and hepatic iron overload. It was more accurate and more sensitive (91.2% vs. 74.7%) for detecting any underlying disease entity.

The computer-aided two-dimensional technique analogously was more sensitive to characterize each disease entity and more accurate compared to the manual two-dimensional and one-dimensional techniques. Review of the color-coded images from livers with combined disease demonstrated a heterogeneous distribution of the areas of abnormality, whose delineation may be useful to guide biopsy or MR spectroscopy.

Conclusions

The manual two-dimensional analysis of two-point Dixon MR images is overall more accurate than the traditional one-dimensional analysis, mainly due to its ability to detect combined hepatic storage disease. The computer-aided technique was even more accurate overall, likely due to the increased number of sampled voxels – average voxels counted by the manual techniques was 113 vs. 3801 voxels counted by the computer-aided technique. The two-dimensional techniques show great promise for detecting these disease entities, especially combined disease, which is undetectable by dual echo MRI assessing in- and opposed phase series only. Additionally, the ability of the color images to show the distribution of disease may help guide biopsy or spectroscopy and reduce the sampling error inherent in these tests.

References

- Chitturi S et al, Curr Gastroenterol Rep, 2003, 5:18-25.
- Kohgo Y et al, J Gastroenterol Hepatol, 2008, 23: Suppl 1, S78-81.
- Westphalen ACA et al, Radiol, February 2009, 242: 2, 450-5.
- Boll DT et al, 17th Ann ISMRM meeting proceedings, 2009, p.4091.

One-Dimensional Disease Discrimination

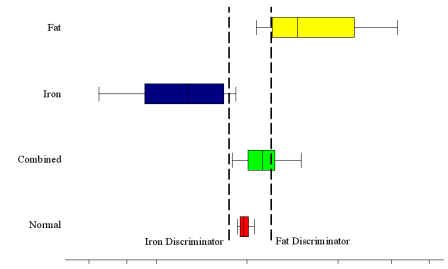


Figure 1 – Shows that combined disease (green) and normal liver (red) cannot be differentiated using I/O analysis alone.

Linear optimization techniques were used to determine the most accurate I/O ratio discrimination levels for detection of voxel clusters representing steatosis hepatis and hepatic iron overload in a one-dimensional approach – analysis of in- and opposed phase Dixon series only, Figure 1. The manual two-dimensional technique determined optimal F/W ratio discrimination levels to differentiate normal from abnormal voxel clusters and further utilized logarithmic regressions to model the relationship between I/O and F/W dependent on underlying storage disease, specifically steatosis hepatis, hepatic iron overload, and combined disease, Figure 2. Finally, these discrimination levels were applied to the computer-aided algorithm implemented as a voxel-by-voxel analysis using the Matlab environment (Matlab R2009b, Natick, MA). This algorithm determined the most likely disease entity present and calculated color-coded images of the areas of abnormality as the computer-aided two dimensional approach, Figure 3.

	Manual 1-D Technique			Manual 2-D Technique				Computer-Aided 2-D Technique			
	Fat	Iron	Abnorm	Fat	Iron	Combined	Abnorm	Fat	Iron	Combined	Abnorm
Sensitivity	75.8%	81.7%	74.7%	81.1%	78.3%	86.7%	91.2%	100%	100.0%	100.0%	100.0%
Specificity	97.5%	98.1%	97.6%	96.4%	98.7%	92.1%	85.9%	96.4%	93.7%	100.0%	86.0%
Accuracy	92.0%	95.5%	87.2%	92.5%	95.5%	91.9%	88.3%	97.3%	94.7%	100.0%	92.0%

Figure 3

