

INTERACTIVE MR-GUIDED PERCUTANEOUS NEPHROSTOMY USING AN OPEN 1T MR-SCANNER: FIRST EXPERIENCE IN 15 PATIENTS

F. Fischbach¹, M. Porsch², J. Bunke³, M. Pech², O. Dudeck², U-B. Liehr², and J. Ricke²
¹OvGU, Magdeburg, Germany, ²OvGU, ³PMS

INTRODUCTION

Usually percutaneous nephrostomy is performed under sonographic guidance in a fluoroscopy suite. Although MR provides detailed images of the upper urinary tract (1,2), there still exist only very preliminary results that have been reported about MR-guided percutaneous nephrostomy (3,4). When sonographic guidance is not possible due to e.g. severe obesity, overlying intestinal gas, or parapelvic cysts MR guidance could be an alternative approach in these cases. The purpose of this study was to assess the safety and feasibility of MR-guided percutaneous nephrostomy (MRPCN) using an open 1.0T scanner and MR fluoroscopic imaging.

MATERIAL AND METHODS

MR guidance and monitoring was performed using a 1.0T open system with vertical field orientation (Panorama, Philips, Best, The Netherlands). A belt-shaped 21-cm-diameter loop receive-only coil was used for signal reception and placed in the region of the kidneys. Imaging and the percutaneous puncture of the collecting system were performed in a prone/semilateral position of the patient. An in-room RF-shielded liquid crystal monitor was used for image display at the side of the magnet analogous to a fluoroscopy monitor. The equipment included an 18-gauge MR-compatible titanium puncture needle, a nitinol guide wire, different tract dilators and a 7.6F nephrostoma-catheter. MR guidance was performed in an interactive continuous scan mode providing 1 image per second with a fluoroscopic fast T2-w single shot 2D TSE sequence (TR/TE 1000/100 ms, FOV 300x300 mm, matrix 2.0x2.4 mm, slice thickness 8 mm) in two orthogonal planes was used to guide the insertion of the needle into a predetermined calyx in freehand technique. The skin entry site was defined with finger pointing. When the needle was placed deeply in the pelvic system the patient was moved out of the magnet to insert the catheter via *Seldinger* technique. Finally the correct placement of the device within the urinary collecting system was confirmed by fat saturated breath hold T1w GRE sequence in coronal orientation after injection of diluted Gd-DTPA into the collecting system (FFE TR/TE 5.4/2.6 ms; flip 12°, FOV 300x300 mm, matrix 1.1x1.3 mm, slice thickness 3 mm).

RESULTS

So far we performed 22 MR-guided nephrostomies in 15 patients. The guiding procedure could be completely performed inside the magnet in all cases

With the help of fluoroscopic interactive continuous imaging in two orthogonal planes, the puncture needle was safely directed into the target calyx. Even slight deviations of the needle from the intended path were detected in both MR image planes, allowing for immediate readjustment of the needle position in free hand technique (fig. 1). All procedures resulted in successful puncture of the calyx. No complications occurred. Under the experimental conditions of the study, the time for planning and placement of the nephrostoma lasted approx. 30 minutes.

DISCUSSION

The advantages of MR fluoroscopy including missing radiation, high tissue contrast, multiplanar imaging and the availability of open high field systems giving good access to the patient and sufficient SNR should encourage broadening the indications for MR-guided interventions. MR-guided percutaneous nephrostomy can be performed in a routine setting. This is especially of interest in patients not suited for sonographic guidance.

REFERENCES

- (1) Roy C, Saussine C, Jahn C, et al. Evaluation of RARE-MR urography in the assessment of ureterohydronephrosis. J Comput Assist Tomogr 1994; 18:601-608;
- (2) Regan F, Bohlman ME, Khazan R, Rodriguez R, Schultze-Haakh H. MR urography using HASTE imaging in the assessment of ureteric obstruction. AJR 1996; 167:1115-1120,
- (3) Hagspiel KD, Kandarpa K, Silverman SG. Interactive MR-guided percutaneous nephrostomy. JMRI 1998; 8:1319-1322,
- (4) Kariniemi J, Sequeiros RB, Ojala R, Tervonen O. MRI-guided percutaneous nephrostomy: a feasibility study. Eur Radiol. 2009 May;19(5):1296-301.

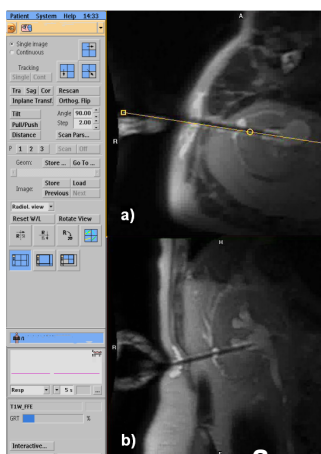


FIGURE 1:

Percutaneous nephrostomy using the interactive mode.

Image planes could interactively be adjusted to image the entrance point and the pelvic system in one plane. Perpendicular to this plane a second plane was imaged to follow the pathway in two perspectives. Images were acquired in continuous mode with a frame rate of 1 image per second.

Finger pointing to determine the entrance point in transversal orientation (a). Puncture of the pelvic system in corresponding coronar orientation (b).