

## Retrospective bellows-based reconstruction for cardiac MRI: preliminary experience

C. Santelli<sup>1</sup>, R. Nezafat<sup>1</sup>, W. J. Manning<sup>1,2</sup>, S. Kozerke<sup>3</sup>, and D. C. Peters<sup>1</sup>

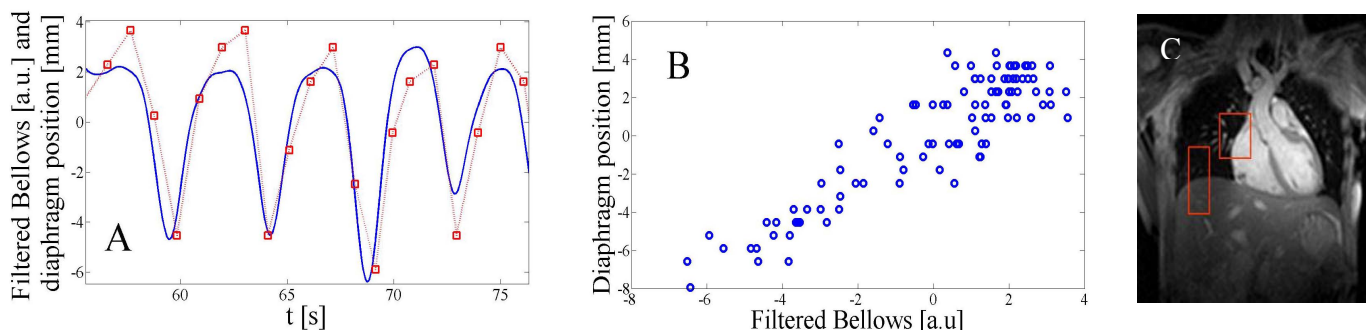
<sup>1</sup>Cardiology, Beth Israel Deaconess Medical Center, Boston, MA, United States, <sup>2</sup>Radiology, Beth Israel Deaconess Medical Center, Boston, MA, United States, <sup>3</sup>D-ITET, ETH Zurich, Institute for Biomedical Engineering, Zurich, Zurich, Switzerland

**Introduction:** The two most common methods for respiratory compensation of cardiac MR (CMR) studies are breath-holding and navigator-gating. Respiratory bellows is a long-established, readily available method, but has been rarely used in cardiac imaging, with some exceptions [1,2,3]. This study compares the performance of respiratory chest wall and abdomen bellows to navigator-gating (NAV), and the actual superior-inferior displacements of the lung-liver interface and the heart. Using the relationship between bellows and heart-motion, 3D coronary MRI was obtained using a retrospective [4] bellows-based reconstruction.

**Methods: Acquisition:** Five healthy subjects were imaged on a Philips 1.5 T Achieva MR scanner, during free-breathing using a single shot 2D balanced SSFP acquisition to obtain 100 images ECG-gated to diastole acquired in 100 consecutive heart-beats, with NAV and bellows-monitoring. Scan parameters were: 35 cm FOV, 116 x 93 matrix, 8mm slice, TR/TE/θ=2.3ms/1.1ms/50°, sequential acquisition order, 200.7 ms acquisition window. Further, a 3D gradient echo coronary MRI sequence was acquired during free-breathing with NAV and bellows-monitoring with acceptance of all data. Scan parameters were: 27cm FOV, 240 x 244 x 13 Nz, TR/TE/θ=5.5ms/1.7ms/30°, 3 mm slices, fat-saturation, T2-prep, ECG-gating to diastole. The k-space volume was collected twice, and raw data was exported.

**Analysis:** The superior-inferior displacements of the diaphragm and the heart was compared to the NAV and bellows data. The relationship of the bellows to the lung-liver interface and to the heart was plotted. Using this relationship, criteria for retrospective acceptance/rejection of data were developed and applied for retrospective bellows-based reconstruction of the multi-frame 3D coronary data, with processing in Matlab.

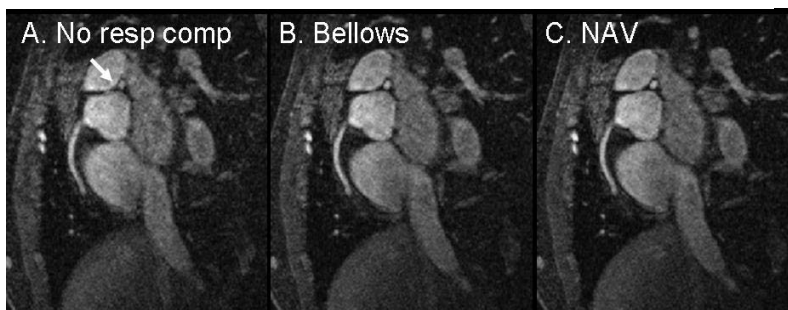**Results:** Figure 1 shows the relationship between bellows and the lung-liver interface. Table 1 presents the correlations between the bellows signal and superior-inferior displacements measured by the NAV and images. Figure 2 compares a retrospective NAV-based, and bellows-based reconstruction of 3D coronary MRI data, to an image without respiratory compensation.



**Figure 1:** A) Abdomen bellows signal, and the superior-inferior position of diaphragm (lung liver interface) measured in images, vs. time. B) The correlation between the bellows and diaphragm. C) A single-shot 2D image showing placement of ROIs for tracking the diaphragm and heart.

<i>R value</i>	<i>Bellows-Abdomen</i>	<i>Bellows-Chest</i>
<i>NAV</i>	0.924 ± 0.046	0.854 ± 0.067
<i>Diaphragm</i>	0.899 ± 0.046	0.816 ± 0.072
<i>Heart</i>	0.884 ± 0.052	0.803 ± 0.021

**Table 1:** Based on data such as in Figure 1 B, the cross-correlation values were calculated for the 5 different subjects, with mean and standard deviations are presented.



**Figure 2:** A slice from a 3D coronary MRI A) without respiratory gating, B) using bellows-gating, C) using retrospective NAV-gating.

**Discussion and conclusions:** Our preliminary study shows that the bellows is strongly correlated to diaphragmatic and heart motion, with greater correlation of the abdomen bellows than chest bellows. Our bellows-based reconstructions provide similar respiratory compensation to the NAV, but with a continuous signal which doesn't interrupt imaging. Our study which revisits the value of bellows-gating for respiratory compensation shows that bellows-gating is promising for cardiac MR.

**References:** [1] Spincemille P et al, ISMRM 2007, 1826. [2] Martinez-Moller A, Eur J Nucl Med Mol Imaging, 34 (9): 1447-1454, 2007. [3] McConnell MV et al, AJR, 168 (5): 1369-1375, 1997. [4] Li D et al, Radiology, 201 (3): 857-863, 1996.