

Monitoring Treatment Response of Prostate Cancer Bone Metastases With the Functional Diffusion Map

C. Reischauer¹, J. M. Froehlich², C. A. Binkert², P. Boesiger¹, and A. Gutzeit²

¹Institute for Biomedical Engineering, University and ETH Zurich, Zurich, Switzerland, ²Department of Radiology, Cantonal Hospital Winterthur, Winterthur, Switzerland

Introduction

Prostate cancer is the most common cancer in men worldwide. 90% of the patients with advanced prostate cancer have skeletal metastases that are presently incurable [1]. Consequently, there is a need for the development of novel therapies for which treatment success has to be monitored.

The functional diffusion map (fDM) has been introduced as a possible non-invasive biomarker of treatment response in brain tumors [2]. It is a voxelwise statistical analysis of the change of the apparent diffusion coefficient (ADC) under therapy that segments the tumor into three distinct regions with increased (marked in red), decreased (displayed in blue), and unchanged ADCs (shown in green). Lee et al. have recently presented a single patient suggesting the fDM as a possible marker of treatment response in prostate cancer bone metastases [3].

In early years, hormone-dependent prostate carcinoma can be treated efficiently with androgen deprivation therapy. Thereby, treatment response can be assessed with the prostate-specific antigen (PSA) value [4]. The present work investigates the feasibility of the fDM to monitor treatment response in prostate cancer bone metastases in a prospective clinical study of patients treated with androgen deprivation therapy for the very first time.

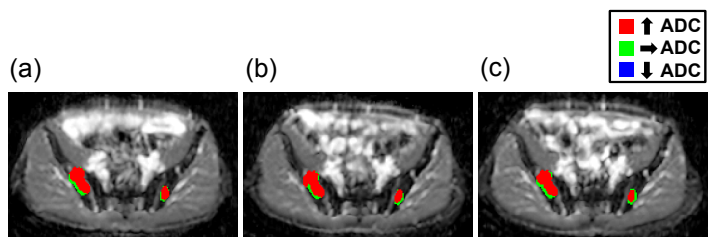


Figure 1: Functional diffusion maps of two metastases in one patient overlaid onto the respective ADC map: (a) 4 weeks, (b) 8 weeks, and (c) 12 weeks after therapy onset with respect to the baseline values.

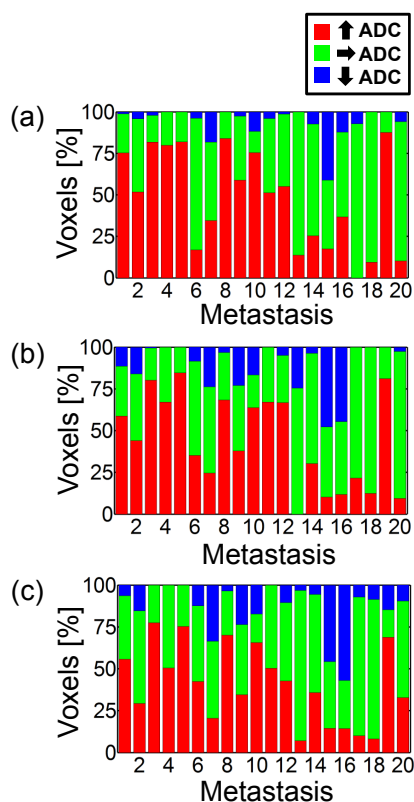


Figure 2: Percentage of ADC changes in all metastases: (a) 4 weeks, (b) 8 weeks, and (c) 12 weeks after treatment begin.

Methods

Patient Population: A total of 9 patients (age range = 66 to 86 years, mean age = 75 years) with histologically proven prostate cancer and known bone metastases in the pelvis were included. The patients did not have prior treatment for prostate cancer and were scheduled for androgen deprivation therapy. In all cases the PSA values were moderately to markedly increased (PSA range = 61 – 1069 ng/ml, mean PSA = 346 ng/ml).

MR-Imaging: MRI was performed prior to treatment onset and 4, 8, and 12 weeks after therapy begin. Thereby, conventional anatomical images and diffusion-weighted images were acquired. Additionally, the PSA values were determined at each timepoint. The scan parameters of the diffusion sequence were as follows: FOV = 400 x 256 x 192 mm, slices = 32, slice thickness = 6 mm, b-values = 0, 200, 400, 600, and 800 s/mm², 3 orthogonal diffusion-encoding directions, TE = 63 ms, TR = 4751 ms, scan time = 12 min 6 s.

Data Analysis: The ADC maps were computed and those acquired after treatment onset were coregistered to the baseline ADC map that was measured prior to therapy. Thereby, coregistration was performed with a robust multiresolution alignment algorithm [5] that was extended in the current work to allow for affine transformations. Regions of interest, circumscribing the bone metastases, were defined manually on the baseline ADC maps by a radiologist with 8 years of experience. Thereafter, the fDMs of each metastasis were calculated for each timepoint after treatment onset with regard to the baseline values. The segmentation threshold was set to the repeatability limit of muscle tissue on a per-patient basis [6]. Additionally a cluster size threshold was set at 6 assuming that treatment response should extend over several voxels.

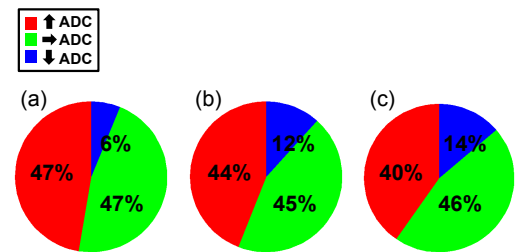


Figure 3: Average percentage of ADC changes in all metastases: (a) 4 weeks, (b) 8 weeks, and (c) 12 weeks after therapy onset.

Results

The PSA values of all patients decreased markedly under therapy indicating good treatment response. The average decrease was 94% within the first 4 weeks and 98% after 12 weeks. The exemplary fDMs in Figure 1 illustrate that the fDM allows resolving the spatial distribution of tumor response under therapy. Figure 2 shows the results of the entire metastasis population at the 3 investigated timepoints. All metastases featured, in parts large, regions with significantly increased ADCs but the extent of tumor response varied. Beyond that most metastases exhibited also minor regions with significantly decreased ADCs. Figure 3 shows the ADC changes averaged over all metastases. Large parts of the tumor volumes showed significantly increased ADCs with the highest value 4 weeks after therapy onset indicating good treatment response. Contrary, significantly decreased ADCs were observed especially later in therapy. A large part of the tumor volume showed unchanged ADCs under ongoing therapy. This might be one of the first signs of the inability of androgen deprivation therapy to cure prostate cancer.

Discussion and Conclusion

The present study demonstrates that the fDM allows monitoring treatment response in advanced prostate cancer patients. In contrast to a simple ROI analysis the fDM thereby allows resolving the spatial distribution of tumor response. Future work should correlate the fDMs directly with histopathological results to investigate the underlying processes on the cellular level, especially the origin of significantly decreased ADCs.

References: [1] Bubendorf L. et al., [2000], Hum Pathol 31: 578-583. [2] Moffat, B.A. et al., [2004], PNAS, 102(15): 5524-5529. [3] Lee, K. C. et al., [2007], Neoplasia, 9(12): 1003-1011. [4] Bubley, G. J. et al., [1999], J Clin Oncol, 17: 3461-3467. [5] Nestares, O. et al., [2000], MRM, 43: 705-715. [6] ISO 5725-6 :2002-008 : 13.