

Vessel size index MRI to monitor the effects of vascular disruption by ASA404 (vadimezan, 5,6-dimethylxanthenone-4-acetic acid) in orthotopic gliomas

K. S. Opstad¹, S. P. Robinson², and F. A. Howe¹

¹Division of Cardiac & Vascular Sciences, St. George's, University of London, London, United Kingdom, ²Cancer Research UK Clinical Magnetic Resonance Research Group, Institute of Cancer Research, Sutton, United Kingdom

Introduction: Gliomas are the most common primary brain tumour type in adults but survival times remain low, irrespective of current treatments. Vascular disrupting agents (VDAs) significantly reduce tumour blood flow; and as gliomas are highly vascularised tumours, VDAs are attractive for developing new treatment strategies. Non-invasive methods of monitoring vascular targeted treatment effects are essential for brain tumours and this study has investigated the use of vessel size index (VSI) MRI to determine the effects of the Tumour-VDA ASA404 (vadimezan, formerly AS1404, 5,6-dimethylxanthenone-4-acetic acid DMXAA) (Novartis Pharma AG, Basel, Switzerland) on fractional blood volume (fBV) and blood vessel size (Rv) in orthotopic C6 rodent gliomas.

Methods: Orthotopic tumours ($n=6$) were grown by stereotactic injection, on Day 0, of a single C6 spheroid ($\approx 200 \mu\text{m}$) into female Wistar rat cortex (2 mm lateral (left), 5 mm depth from Bregma) - tumour spheroids provide an improved model of human glial invasion. MRI was performed on Day 23 post-implantation with a 4.7T Varian Unity INOVA using a dedicated rat brain coil (body coil transmit with 15 mm diameter receive coil, Rapid Biomedical, Germany). From a pilot study of this orthotopic glioma model, T_1 -weighted images post-gadolinium (Gd-DTPA) indicated blood brain barrier breakdown at beyond Day 22 post-implantation. 11 axial images were acquired for each tumour (1 mm contiguous) with a 512×256 matrix and a 6.4 cm FOV with: MGRE (TR 100 ms, TE 5, 11, 17 & 23 ms with 8 echoes, flip angle 20°) and SE (TR 1000 ms, TE 12 & 40 ms). MGRE and SE images were acquired pre-contrast and at 5 minutes after intravenous administration of a USPIO blood pool contrast agent Ferumoxtran-10 (Sinerem[®], Guerbet, France) at a dose of $200 \mu\text{mol Fe kg}^{-1}$ body weight via a tail vein cannula. Following MRI (Day 23), rats were given ASA404 (350 mg kg^{-1} , $n=3$) intraperitoneally, or volume matched saline as a control ($n=3$). MRI was repeated at 24 hours post-treatment (Day 24). MRI data was analysed using ImageBrowser (Varian Inc.) to create fBV and Rv maps¹. Excessively large Rv values arising from pixels with low SNR or very low fBV were prevented by using a threshold of $\Delta R_2 > 1 \text{ s}^{-1}$; an estimation of the lower limit accuracy of calculating ΔR_2 . Regions of interest (ROIs) encompassing non-necrotic areas of tumour (thereby assuming viable tumour tissue) and contralateral normal tissue were defined from pre-contrast SE (TE 40 ms) images and the VSI parameters for each group pre- and post-treatment calculated. Histogram analyses were performed over these ROIs for fBV and Rv. A single apparent diffusion coefficient was assumed as the VSI calculation is much less sensitive to the ADC than relaxation rate changes².

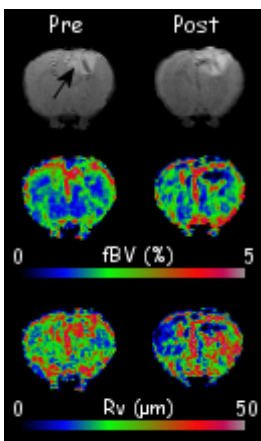


Figure 1

Results: In Figure 1 [SE (top), fBV maps (middle) and VSI maps (bottom)], there is greater blood volume and vessel size in the tumour area (indicated by black arrow) pre-treatment as compared to contralateral normal brain. Post-treatment there is a reduction in the fBV and VSI indicating a response to ASA404. Histogram analysis over all data revealed a significant increase in the number of pixels with $\text{fBV} < 0.4\%$ at 24 hours post-ASA404 treatment ($p=0.049$, paired t-test and Figure 2a). Although there is a shift of the whole histogram towards a lower fBV post-ASA404 treatment, there was no significant change in median tumour blood volume. The vessel size histogram (Figure 2b) also shows a trend towards a reduction in blood vessel size, with a clear shift to the left in the post-treatment Rv histogram when compared to pre-treatment, but this did not reach statistical significance. The saline group showed no significant differences between pre- and post-treatment in any of the measured VSI parameters.

Discussion: The post-ASA404 treatment histogram shift towards reduced fBV (Figure 2a) and increase in $\text{fBV} < 0.4\%$ is consistent with the expected effects of ASA404 to cause vascular collapse in tumours². A recent ASA404 study has also shown post-treatment increases in Gd-DTPA accumulation in orthotopic gliomas; similarly indicative of treatment-induced vascular disruption³. The fBV and VSI maps in Figure 1 indicate a large reduction in fBV and Rv in the tumour centre of the post-treatment images (dark blue/black area), which are suggestive of development of a necrotic core. The left shift of the Rv histogram in (Figure 2b) is also consistent with vascular collapse. Although there was no statistical significance in the reduction of median Rv post-treatment, this may reflect differences in sampling for the ROIs of viable tumour tissue pre- and post-treatment because with the development of a necrotic core there are increased areas for which VSI measurement are not possible. Additionally the current data-set is of a small number of tumours. Although we have shown a significant decrease in fBV in response to ASA404, there was no reduction in tumour size, with both groups (ASA404 and saline) showing similar increases in tumour volume over the 24 hour period pre- and post-treatment. VDAs damage existing tumour vessels, but since gliomas are highly angiogenic, it is widely acknowledged that co-treatment of tumours with both VDAs and angiogenic inhibitors to also prevent formation of new blood vessels may represent one potential combination treatment strategy.

In conclusion, use of an exogenous blood pool contrast agent with histogram analysis appears to be an effective method of non-invasively monitoring the treatment effects of the Tumour-VDA ASA404 on brain tumour vasculature.

In conclusion, use of an exogenous blood pool contrast agent with histogram analysis appears to be an effective method of non-invasively monitoring the treatment effects of the Tumour-VDA ASA404 on brain tumour vasculature.

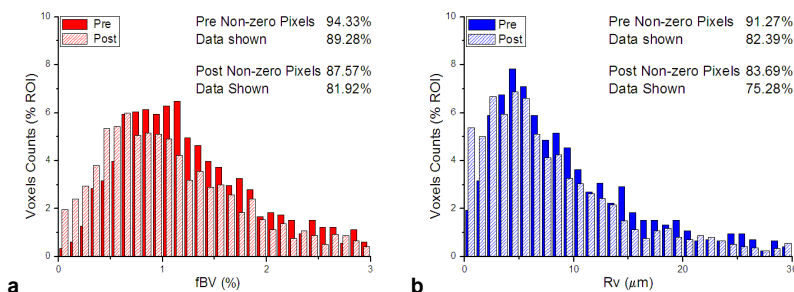


Figure 2

References

- [1] Tropes I, et al. *Magn Reson Med* **45**:397-408; 2001.
- [2] Howe FA, et al. *Int J Radiation Oncology Biol Phys* **71**:1470-76; 2008.
- [3] Seshadri M, et al. *J Cereb Blood Flow Metab* **29**:1373-82; 2009.

Acknowledgements

This work was funded by the Neuroscience Research Foundation and the Association of International Cancer Research (AICR) Grant Number: 09-0310. Sinerem[®] (supplied by Guerbet) and ASA404 (supplied by Novartis Pharma AG) were supplied under material transfer research agreements.