

Quantitative Osteosarcoma DCE-MRI: How Long is the Acquisition Time Necessary?

Y. Wang¹, W. Huang², D. M. Panicek¹, L. H. Schwartz¹, and J. A. Koutcher¹

¹Memorial Sloan Kettering Cancer Center, New York, NY, United States, ²Oregon Health & Science University, Portland, OR, United States

Introduction

We have recently shown that quantitative pre-surgery dynamic contrast-enhanced (DCE) MRI can potentially be an important imaging biomarker for accurate prediction of therapeutic response and long-term survival of patients with osteosarcomas (1). However, patient discomfort and resulted motion are consistently problematic during a DCE-MRI study of 5 min or longer. Therefore, without affecting accuracies of the derived pharmacokinetic parameters, shorter DCE-MRI acquisition time length should be used in order to reduce patient discomfort and obtain good-quality data. In this study, through simulations based on the pharmacokinetic parameters extracted from the real DCE-MRI data, we sought to determine the minimum acquisition time that is required to obtain accurate and stable estimations of K^{trans} and v_e values from osteosarcoma DCE-MRI data.

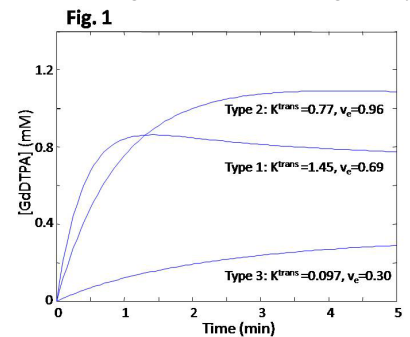
Methods

Prior to definitive surgeries, 18 patients with osteosarcomas in the knee area underwent DCE-MRI scans to evaluate the efficacy of chemotherapy in inducing tumor necrosis. The DCE-MRI study was IRB-approved, and informed consent was obtained from each patient. All data acquisitions were performed at 1.5T with a fast multiplanar SPGR sequence, 30° flip angle, 2.9 ms TE, 7.5-9.0 ms TR, 20-24 cm FOV, and 256x128 matrix size. The entire tumor was imaged with 8-11 sections of 10-12 mm thickness. The total DCE-MRI acquisition time was between 5 to 10 min with 7-10 sec temporal resolution and 30-60 time course data points. At the beginning of the sixth image set acquisition, GdDTPA (0.1 mmol/kg) was administered intravenously with a rate of 1 cc/sec or 2 cc/sec by a programmable power injector. The variation in injection rate was due to the location and the size of the IV catheter. In order to estimate R_1 for each DCE-MRI time-course data point, proton density images were acquired prior to DCE-MRI using the same pulse sequence (2).

The tumor ROI signal time-course from each image section and an average femoral artery AIF (obtained from individual measurements in five patients) based on 2 cc/sec contrast injection rate were subjected to kinetic modeling using the Toft's model (3). We have shown that it is feasible and reasonable to use limited-population-based average AIF for quantitative analysis of osteosarcoma DCE-MRI data obtained with either 1 or 2 cc/sec contrast injection rate (4). Whole tumor K^{trans} and v_e values were calculated by averaging those of the image section ROIs, weighted by the number of pixels in each ROI. These values from all 18 patients, in combination with the same average AIF, were then used to re-construct simulated contrast concentration time-courses with varying scan time length: from 0.5 min after contrast injection to 20 min with 0.05 min interval. White Gaussian noise with mean = 0 and variance = 0.001 were added to the simulated curves to mimic real data. With increasing acquisition time, the length beyond which the K^{trans} or v_e value derived from the simulated time-courses changes less than 1% was considered the minimal acquisition time needed to obtain an accurate and stable estimation of the pharmacokinetic parameter.

Results

Surgical pathologies revealed a wide range of tumor necrosis percentage: 10-100%. Consequently, the derived whole tumor K^{trans} and v_e values had broad ranges of 0.078 – 1.45 min^{-1} and 0.24 – 0.96, respectively. **Fig. 1** shows simulated curves of three typical DCE-MRI time-courses based on real data from three patients: Type 1, quick wash-in and wash-out ($K^{\text{trans}} = 1.45 \text{ min}^{-1}$, $v_e = 0.69$); Type 2, moderate wash-in and plateau wash-out ($K^{\text{trans}} = 0.77 \text{ min}^{-1}$, $v_e = 0.96$); Type 3, slow wash-in and persistent rising ($K^{\text{trans}} = 0.097 \text{ min}^{-1}$, $v_e = 0.30$). These three curve types correspond to low, moderate, and high necrosis percentage, respectively, in correlation with the pathology findings.



	Type 1	Type 2	Type 3
K^{trans}	1.0 min	2.0 min	3.2 min
v_e	1.1 min	2.4 min	4.6 min

the dominant factor: larger K^{trans} ($> 0.5 \text{ min}^{-1}$) requires accurate and stable derivation of either K^{trans} or v_e . In general, longer acquisitions are needed for small K^{trans} and large v_e pairs (upper-left area of Fig. 2), while shorter acquisitions are usually adequate for large K^{trans} and small v_e pairs (lower-right area of Fig. 2).

Discussion

The results from this study suggest that for the typical osteosarcoma K^{trans} and v_e ranges, a DCE-MRI acquisition time length of no less than 4.6 min is sufficient for accurate and stable derivations of the pharmacokinetic parameters. If K^{trans} is the only parameter of interest, such as in a longitudinal study of tumor response to antiangiogenic therapy, the acquisition time can be even shorter (3.2 min). Therefore, any osteosarcoma DCE-MRI acquisition time beyond the 5-min mark is probably unnecessary for accurate pharmacokinetic analysis of the time-course data. The short acquisition time will speed-up DCE-MRI protocol, reduce patient discomfort, and minimize the possibility of motion.

References 1. Koutcher JA, et al. Proc Int Soc Magn Reson Med 2008;16:767. 2. Huang W, et al. Magn Reson Imaging 2009;27:852-858. 3. Tofts PS. JMRI 1997;7: 91-101. 4. Wang Y, et al. Magn Reson Med 2008;59:1183-1189.

The **Table** lists the minimal DCE-MRI acquisition times required to obtain stable estimations of K^{trans} and v_e for the three curve types. Type 3 curve demands the longest acquisition time for accurate kinetic analysis, though no more than 5 min is needed. **Fig. 2** shows the minimal scan time required (in color scale) for each of the 18 pairs of K^{trans} and v_e : whether a stable K^{trans} (Fig. 2a) or v_e (Fig. 2b) value is of interest. K^{trans} value appears to be

