

EVALUATING AND RELATING CONTRAST MECHANISMS IN PROSTATE CANCER: HETEROGENEITY WITHIN NORMAL AND TUMOR REGIONS AT 3.0 T

S. Giles¹, S. F. Riches², V. A. Morgan¹, C. Simpkin¹, and N. deSouza²

¹Cancer Research UK and EPSRC Cancer Imaging Centre, Royal Marsden NHS Foundation Trust, Sutton, Surrey, United Kingdom, ²Cancer Research UK and EPSRC Cancer Imaging Centre, Institute of Cancer Research & Royal Marsden NHS Foundation Trust, Sutton, Surrey, United Kingdom

Introduction: Detection of tumor within the prostate currently depends on T2-weighted contrast, but poor discrimination between tumor and normal prostate tissue, particularly in the central gland has demanded exploration of alternate contrast mechanisms. Diffusion-weighted MRI (DW-MRI) is increasingly used to aid detection of prostate cancer [1] where tissue contrast is attributed to cellularity although histological evidence is inconclusive. Magnetisation transfer imaging also has been shown to improve tissue contrast [2,3], because in tissues with abundance of large macromolecules, their selective pre-saturation results in a decreased water signal. Although a positive correlation between T2 and apparent diffusion coefficient (ADC) and a negative correlation between ADC and magnetization transfer ratio (MTR) has been shown at 1.5T [4], variability in measured values can be large particularly if signal to noise ratio (SNR) is low. The purpose of this study was to determine T2 values, ADCs and MTRs in normal regions of the prostate and prostate tumors at 3T which affords improved SNR, document the variability in the measured parameters and the relationship between them.

Method: 20 men (mean age 77 ± 7 years) with biopsy-confirmed prostate cancer were studied using a 3T Achieva MR scanner (Philips Medical Systems, Best, Netherlands) with an endorectal receiver coil, inflated with 60ml of air and a cardiac phased array coil. All patients were imaged prior to any treatment. Gleason scores were 3+3(n=17), 3+4(n=2), 4+3(n=1). PSA ranged from 4.6-33.3ng/mL (mean 11.6 ± 6.8). In addition to standard 3-plane imaging (TSE, TR/TE=3643/110, 20slices, 2.2mm thickness, 220x184matrix, 120mm FOV), 20 axial slice diffusion-weighted images (TR/TE 5129/65, 2.2mm thickness, 180mm FOV, 128x128 matrix, 5 b-values 0,100,300,500,800 s/mm² in three directions) were acquired and ADCs were calculated using all b-values. An MTR sequence (3DFFE, TR/TE=211/3.7, 24slices, 2.2mm thickness, 120x138 matrix, 120mm FOV) was acquired with and without an off-resonance magnetisation transfer pre-pulse. A multi-echo sequence (GraSE, TR=30000 TE=20/40/60/80/100, 20 slices, 2.2mm thickness, 120mm FOV, 132x105 matrix,) was acquired and the T2 maps generated using the scanner software. MTR was calculated as the percentage reduction in signal between the images with and without the magnetisation transfer pre-pulse. An experienced radiologist drew regions of interest (ROI) on the images in areas of tumour (TU, hypointense focal lesions on the T2-weighted images in a biopsy positive octant), normal central gland (CG) and normal peripheral zone (PZ). ROIs were transferred onto ADC, T2 and MTR maps by matching slice positions. Coefficient of variation (SD/mean) of each parameter for each region were compared (paired samples t-test). Correlations between T2, ADC and MTR were examined using Pearson's correlation coefficient.

Results: Differences between mean T2, ADC and MTR values between normal PZ and TU were significant ($p=0.005$, $p=0.002$ and $p=0.03$ respectively, Table 1). Differences between PZ and CG were significant for T2 and MTR, ($p<0.0001$, $p=0.049$ resp) but not for ADC. Differences between TU and CG were not significant for any parameter. Coefficient of variation was high for both T2 and MTR, particularly in the normal regions of the prostate. ADC showed the least variability for all regions Fig. 2. ROC curves confirmed that ADC provided the best discrimination between TU and non-TU ROIs (AUC=0.75). Discrimination was less good for T2 (AUC=0.64) and MTR(AUC=0.5). There was a weak negative correlation between ADC and MTR ($r=-0.268$, $p=0.039$) and between MTR and T2 ($r=-0.294$, $p=0.023$) and a weak positive correlation between ADC and T2 ($r=0.254$, $p=0.05$).

	Tumor	Peripheral Zone	Central Gland
T2 (ms)	101 ± 34 100 (42-167)	116 ± 31 111 (61-189)	116 ± 35 114 (46-195)
ADC (x10 ⁻⁶ mm ² /s)	1434 ± 252 1382 (936-2069)	1675 ± 156 1674 (1441-1947)	1507 ± 100 1504 (1361-1671)
MTR	0.18 ± 0.04 0.18 (0.11-0.25)	0.16 ± 0.02 0.16 (0.11-0.21)	0.17 ± 0.02 0.17 (0.12-0.21)

Table 1: Measured values (mean ± sd top, median and range bottom) of T2, ADC and MTR in the tumor, peripheral zone and central gland.

Discussion: The lower coefficient of variation of ADC compared to other parameters makes it more reliable at differentiating TU from non-TU in the prostate. Also, it appeared to discriminate TU better as evidenced by the ROC curves. The negative correlation between ADC and MTR suggests that regions of restricted water diffusion have higher magnetization transfer effect.

Conclusion: ADC is the most reliable parameter for differentiating tumor within the prostate. Negative correlation of ADC with MTR suggests that DW contrast may be linked to features other than cellularity, either within cells or in the surrounding matrix, with presence of large macromolecules playing a role.

References [1] Shimofusa R *et al* J Comput Assist Tomogr 2005; 29(2):149-153. [2] Wolfe, SD *et al*, Magn Reson Med 1989;10:135-44 [3] Henkleman, RM *et al*, NMR Biomed 200;14:57-64. [4] Riches, S *et al* ISMRM 2009 #4247 **Acknowledgements:** We acknowledge the support received from the CRUK and EPSRC Cancer Imaging Centre in association with the MRC and Department of Health (England) grant C1060/A10334, also NHS funding to the NIHR Biomedical Research Centre. SR is funded by a Personal Award Scheme Researcher Developer Award from the NIHR.

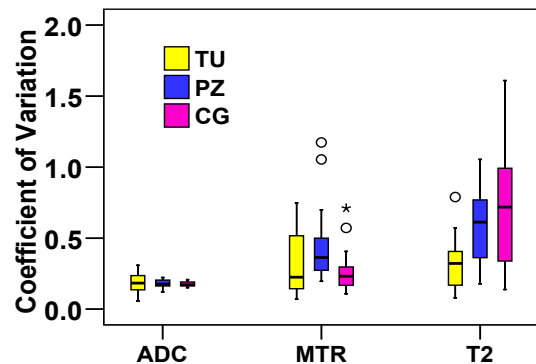


Fig 1: Coefficient of Variation for the three parameters for tumor (yellow), peripheral zone (blue) and central gland (pink).

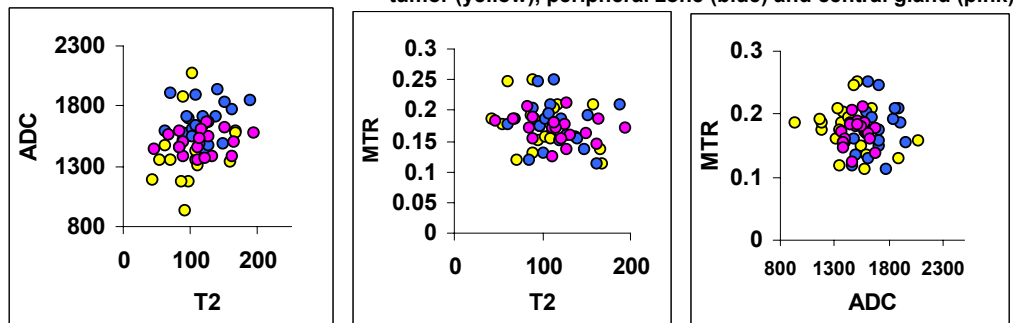


Fig 2: Correlation between T2 and ADC (left), and MTR and T2 (centre) and MTR and ADC (right) for tumor (yellow), peripheral zone (blue), central gland (pink).