

# Diffusion-weighted imaging of uterine endometrial cancer using the apparent diffusion coefficient value at 3.0 T MRI: Differentiation endometrial cancer from normal endometrium and endometrial benign lesions

T. Kamiyama<sup>1</sup>, Y. Fukukura<sup>2</sup>, K. Takumi<sup>2</sup>, T. Shindo<sup>2</sup>, Y. Kumagae<sup>2</sup>, A. Tateyama<sup>2</sup>, T. Tsuji<sup>3</sup>, T. Douchi<sup>3</sup>, and M. Nakajo<sup>2</sup>

<sup>1</sup>Department of Radiology, National Hospital Organization Kagoshima Medical Center, 8-1 Shiroyama-cho, Kagoshima City, Kagoshima, Japan, <sup>2</sup>Department of Radiology, Kagoshima University Graduate School of Medical and Dental Sciences, 8-35-1 Sakuragaoka, Kagoshima City, Kagoshima, Japan, <sup>3</sup>Department of Reproductive Pathophysiology and Obstetrics-Gynecology, Kagoshima University Graduate School of Medical and Dental Sciences, 8-35-1 Sakuragaoka, Kagoshima City, Kagoshima, Japan

## Purpose

Uterine endometrial cancer is the most common gynecological malignancy and the incidence is rising. On the other hand, uterine endometrial hyperplasia and polyps are benign lesions, and should be differentiated from malignant lesions. Diffusion-weighted (DW) magnetic resonance (MR) imaging has been applied to the abdominal organs, and apparent diffusion coefficient (ADC) value of the tissue has been known to characterize malignant or benign lesions, recently. The purpose of this study was to evaluate the feasibility of DW single-shot echo-planar imaging sequence at 3.0 T MR imaging in the evaluation of uterine endometrial cancer, and to investigate whether the ADC values distinguish endometrial cancer from normal endometrium and benign endometrial lesions such as endometrial hyperplasia and polyps.

## Subjects and Methods

A total of 95 females were included in this study. Thirty-nine of the females (mean age, 57.6 years; age range, 32-84 years) were pathologically proven to have endometrial cancer, 43 females (mean age, 47.3 years; age range, 28-72 years) with other suspected gynecologic abnormalities had the normal endometrium confirmed by pathological examination following total hysterectomy, and 13 females (mean age, 49.1 years; age range, 30-72 years) were pathologically proven to have endometrial hyperplasia or polyps. MR examination was performed using a 3.0 T system. DW imaging was obtained with a single-shot echo-planar imaging sequence using parallel imaging technique and chemical shift selective fat suppression technique. Diffusion gradients were applied in 6, 12 or 30 directions with two b magnitudes (0 and 1000 s/mm<sup>2</sup>). ADC values of endometrial lesions and normal endometrium were measured on the ADC map. A Kruskal Wallis test and Mann-Whitney test was used to compare ADC values among the groups, and the differentiation between ADC value and histological grade of the endometrial cancer was also evaluated.

## Results

The mean ADC value of endometrial cancer was  $0.85 \pm 0.21 \times 10^{-3} \text{ mm}^2/\text{s}$ , which was significantly lower than that of normal endometrium ( $1.30 \pm 0.24 \times 10^{-3} \text{ mm}^2/\text{s}$ ,  $p < 0.001$ ) and benign endometrial lesions ( $1.72 \pm 0.57 \times 10^{-3} \text{ mm}^2/\text{s}$ ,  $p < 0.001$ ). In the endometrial cancer group, the mean ADC value for each histological grade was  $0.84 \pm 0.21 \times 10^{-3} \text{ mm}^2/\text{s}$  (grade 1), and  $0.84 \pm 0.18 \times 10^{-3} \text{ mm}^2/\text{s}$  (grade 2 and grade 3), respectively. The mean ADC value of benign endometrial lesions was significantly higher than that of G1 tumors and G2 and G3 tumors, but there was no significant difference between that of G1 tumors and G2 and G3 tumors. With a cutoff ADC value of  $1.2 \times 10^{-3} \text{ mm}^2/\text{s}$  for obtaining the highest accuracy to distinguish endometrial cancer from benign endometrial lesions, sensitivity was 100%; specificity, 81.3%; and accuracy, 94.2%.

## Conclusion

This study showed that diffusion-weighted MRI and ADC values are feasible in distinguishing endometrial cancer from normal endometrium and endometrial benign lesions such as endometrial hyperplasia and polyps.

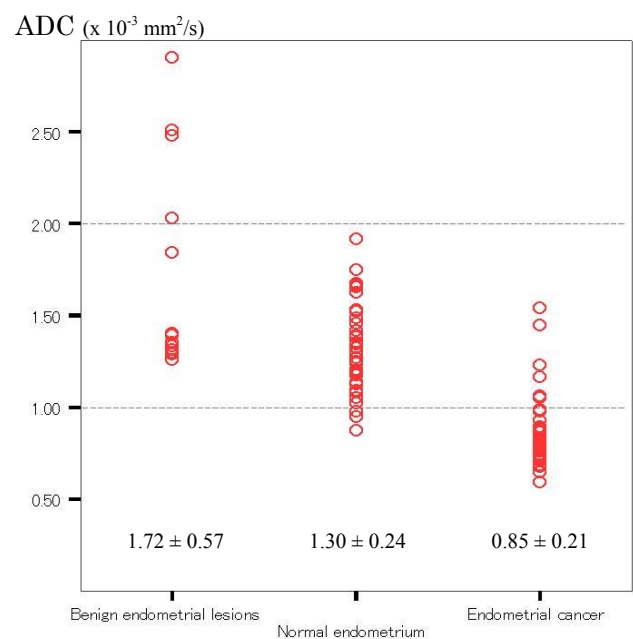


Fig. 1 Scatter plots of the ADC values obtained in benign endometrial lesions, normal endometrium and endometrial cancers. The ADC values are significantly different among the groups ( $p < 0.01$ ).