

The role of magnetisation Transfer imaging in the differentiation of malignant and benign tissues

R. G. Sah¹, U. Sharma¹, R. Prashad², and N. R. Jagannathan¹

¹Department of NMR and MRI facility, All India Institute of Medical Sciences, New Delhi, India, ²Department of Surgical Disciplines, All India Institute of Medical Sciences, New Delhi, India

Objectives: To evaluate the potential of MT imaging in the discrimination of malignant and benign breast tissues.

Introduction: Breast cancer is a major health problem in women worldwide. The diagnosis of the breast cancer is based on palpation, mammography and ultrasonogram. MR imaging and MR spectroscopy has the potential to facilitate improved diagnosis in patients with breast lesions. In conventional MRI, the contrast between different tissues is dependent on the relaxation properties of the water. However to increase the information content, another contrast mechanisms with the use of magnetization transfer (MT) that utilizes the interaction of water protons with macromolecular protons have been explored. Several studies reported the role of MT imaging (MTI) in image contrast improvement and lesion characterisation (2-5). However, there is only one study in the evaluation of breast lesions (2). The objective of this study is to demonstrate the role of MTI in the differentiation of malignant and benign breast tissues.

Materials And Methods: Total of 72 womens; 57 women with cytologically proven infiltrating ductal carcinoma (43.8 ± 9.0 , range 28-67 yrs); 10 benign cases (28.3 ± 9.5 , range 15-38 yrs) and 5 normal volunteers (38.5 ± 15.4 , range 21-59 yrs) were recruited for this study. Written informed consent was obtained and Institutional ethical committee approved the study. MR investigations were performed using a phased array breast matrix coil at 1.5 T whole-body scanner (Avanto, Siemens, Germany). The pulse sequence used for MTI consisted of an off-resonance saturation pulse immediately before the first 90° RF pulse. Two data sets of transverse images with and without MT pulse were acquired keeping all the other parameters identical. The parameters used were: pulse length, 7680 μ s; bandwidth, 250 Hz; frequency offset, 1500 Hz; and flip angle, 500°. Images with and without MT pulse used for MTR calculation were acquired using a TR of 848-1000 ms and a TE of 17ms with a slice thickness of 3 or 4 mm. These values of TR and TE were chosen to minimize T1 and T2 effects (4). The amount of MT was quantified by the calculation of MT ratio (MTR) using the equation $MTR = [1 - M_s/M_o] \times 100$, where M_o is the signal intensity of a given ROI without MTC and M_s is the signal intensity of the same ROI with MT. Signal intensities were measured by drawing free hand ROIs of the whole lesions. MTR was also calculated from adipose and fibroglandular tissues of 10 malignant and benign and 5 normal volunteer. Student's t-test was applied to compare MTR between malignant and benign lesions and Kruskal Wallis test was applied for various breast tissues (adipose and fibroglandular tissues) in malignant, benign and normal breast tissues. A p value of <0.05 was considered significant. ROC between malignant and benign was calculated using SPSS 11.5.

RESULTS: Table-1 gives mean MTR values in various breast tissues. The mean MTR ratio value for malignant breast tissues was 15.1 ± 8.9 which was significantly higher ($p=0.01$) compared to that obtained for benign lesion (11.5 ± 2.9). The MTR for adipose and fibroglandular tissues among malignant, benign and normal was statistically insignificant $p>0.05$. A cut-off

value to differentiate between malignant and benign breast tissues was worked out using the ROC analysis (Fig-2). Accordingly, a cut-off value of 11.9 with sensitivity 71% and specificity 70% for MTR value was obtained to differentiate malignant from benign lesions with the area under ROC curve (AUC) 0.68.

DISCUSSIONS: MTI is a promising tool for tissue characterization and reflects the microstructural changes that accompany the pathological processes. It provides a quantitative index of the structural integrity of tissues. In the present study, we have demonstrated the diagnostic potential of MTI in the discrimination of malignant and benign lesions. Our results showed that the mean MTR value for malignant tumors was significantly higher compared to that obtained for benign lesions. Similarly, several studies reported higher MTR value for the malignant compared to benign tumors (6,7). Our MTR values detected for malignant lesions, adipose and fibroglandular tissues are in agreement with the only study available on breast lesions by Ruth Helen et al. (2). However, the MTR values observed for benign lesions was found to be lower in our study compared to the earlier report (2). The degree of MT contrast within a tissue is primarily governed by the local concentration of macromolecules and thus varies among various tissue types. Cell membrane proteins and phospholipids mainly contribute to the MT signal. Change in MTR may reflect abnormal cell membrane structure or decreased cell number or cell size (8). An increase in the amount of high molecular weight material in cellular nuclei is reported in malignancy (9). The higher value of MTR in malignant lesions compared to benign lesions might arise due to increase in the macromolecular component of breast cancer. Our data suggest the possible role of MTI in the differentiation of malignant from benign lesions, however, further study in large cohort of benign breast lesions are required.

References: (1) Wolff SD et al. Magn Reson Med 1989;10:135-44; (2) Ruth Halena MB et al. MRM 2008;59:1030-34 (3) Wolff SD et al. Radiology 1994;192:593-9. (4) Finelli DA. Magn Reson Imaging Clin N Am 1998;6:31-52. (5) Henkelman RM et al. NMR Biomed 2001;14:57-64. (6) Seo GS et al. Acad Radiol. 1998;5:634-41; (7) Mdgwy Suk Seo et al. Academic Radiology. 1998;5:634-41; (8) Dousset V et al. Neuroradiology 1994;36:188-92.(9) Kurki T et al. Magn Reson Imaging 1995;13:501-11.

	Malignant	Benign	Normal
Adipose	$2.6 \pm 5.7, (n=10)$	$2.6 \pm 2.5, (n=10)$	$4.3 \pm 2.3, (n=5)$
Fibroglandular	$8.3 \pm 12.6, (n=10)$	$12.0 \pm 3.6, (n=10)$	$12.4 \pm 3.6, (n=5)$
Lesion	$15.1 \pm 8.9, (n=57)$	$11.5 \pm 2.9, (n=10)$	

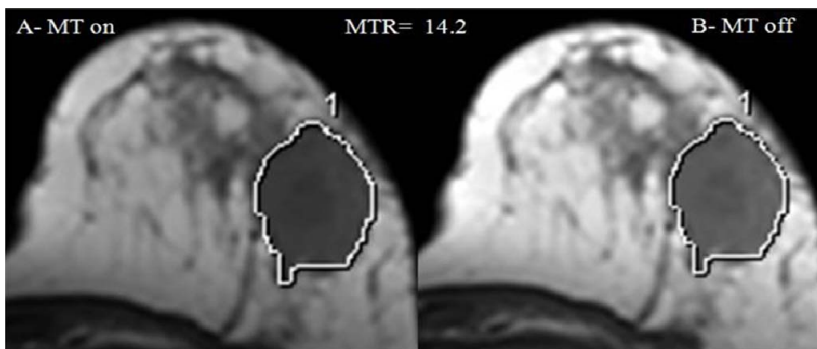


Fig-1- Images from a sequence with magnetisation transfer (A) MT on and sequence without magnetisation transfer (B) MT off of a breast cancer patient.