

# Susceptibility of the optic nerve and the involvement of retrograde neuronal degeneration in a delayed radiation induced injury model: evidence from a diffusion tensor imaging study

D. Qiu<sup>1</sup>, S. Wang<sup>1,2</sup>, K-F. So<sup>3</sup>, E. X. Wu<sup>4</sup>, L. H-T. Leung<sup>5</sup>, and P-L. Khong<sup>1</sup>

<sup>1</sup>Diagnostic Radiology, The University of Hong Kong, Hong Kong, China, People's Republic of, <sup>2</sup>Radiology, Johns Hopkins University, Baltimore, Maryland, United States, <sup>3</sup>Anatomy, The University of Hong Kong, <sup>4</sup>Laboratory of Biomedical Imaging and Signal Processing, The University of Hong Kong, <sup>5</sup>Oncology, Princess Margaret Hospital, Hong Kong, China, People's Republic of

**Introduction:** Treatment-induced radiation injury to the normal white matter is a major cause of morbidity in tumour survivors who have undergone whole-brain irradiation. Diffusion Tensor Imaging (DTI) has been found to be sensitive in detecting such injuries. In our previous study of delayed radiation induced white matter injury in an animal model, we evaluated the longitudinal changes of DTI indices in white matter following radiation and their histological correlations in a single anatomical region (1). As there are evidences of regional susceptibility to radiation from studies on the human brain and animal spinal cord (2, 3, 4), we extend our previous study to evaluation of multiple white matter tracts with the aim of studying regional radio-sensitivity among white matter tracts. We hypothesized that there would be different degrees of susceptibility to radiation among different anatomical regions, and particularly the optic nerve and the optic tract would be more susceptible than other white matter regions as implicated in clinical reports (4).

**Methods:** Nineteen twelve-week-old female Sprague-Dawley (SD) rats were included in the present study. Among them, seven rats formed a truly longitudinal dataset as they were imaged at all time points, while the other 12 rats were sacrificed at different time points for correlation of imaging results with histological findings. The rats received irradiation of 25Gy ( $n=7$ ) or 30Gy ( $n=12$ ) targeted at the frontoparietal region of the right hemisphere, with an accuracy of 1mm for the radiation isocenter. MRI scans were performed at 4 weeks ( $n=11$ ), 24 weeks ( $n=11$ ), 36 weeks ( $n=11$ ), 40 weeks ( $n=7$ ) and 48 weeks ( $n=7$ ) after radiation using a 7T MRI scanner (Bruker, Germany). Coronal T2-weighted MR images were obtained using the following parameters: TR/TE=11189/20ms, FOV=2.5 x 2.5cm<sup>2</sup>, acquisition matrix=128 x 128, slice thickness=1mm. DTI was performed covering from a position 2mm anterior to the rostral end of the corpus callosum to the end of the cerebrum. DTI was acquired with a respiration-gated spin echo 4-shot EPI readout sequence with an encoding scheme of 30 gradient directions homogeneously distributed on the unit sphere. The following parameters were used for DTI: TR/TE=3000/32ms,  $\Delta=15$ ms,  $\delta=5$ ms, FOV=3.0 x 3.0cm<sup>2</sup>, slice thickness=1mm, acquisition matrix=256 x 256, b value =0 and 1000 s/mm<sup>2</sup>. Regions of interest (ROIs) were manually placed on six white matter tracts including the external capsule (EC), fornix, cerebral peduncle (CP), anterior commissure (AC), optical nerve (ON) and optical tract (OT) in both hemispheres at six time points on FA map slice-by-slice and the mean value was calculated (Fig. 1). Paired t-test was used to detect statistical differences in FA values in the white matter tracts between the ipsilateral and the contralateral hemispheres. A p value of <0.05 was considered statistically significant. In order to obtain quantitative value of radiation dose to the white matter tracts, dose distribution map from a representative rat was coregistered to DTI image using CT image as a medium, which is intrinsically registered with the dose map. The radiation dose to white matter tracts was calculated by transferring the ROIs defined in FA image as described above to the dose distribution image. As we were evaluating relative susceptibility between white matter tracts, relative dose, which was defined as the ratio between the actual dose and the prescribed dose, was reported for all the white matter tracts. Rats were sacrificed for histological evaluations of white matter tracts at 4 weeks ( $n=4$ ), 24 weeks ( $n=4$ ), 36 weeks ( $n=4$ ) and 48 weeks ( $n=7$ ) after radiation. Standardized H&E stain was used to detect morphologic characteristics of brain tissues. Luxol fast blue (LFB) stain was performed to detect myelin in the white matter. Immunohistochemical evaluation of axonal damage was performed by using primary antibody against monoclonal antibody to pan-axonal neurofilament (NF) marker. The presence of blood vessel dilation or blood vessel wall thickening, necrosis, demyelination and axonal degeneration were assessed in white matter tracts.

**Results:** The relative dose to the ipsilateral tracts was: EC, 1.18; Fornix, 1.19; CP, 1.05; AC, 0.99; OT, 1.04; ON, 0.65. The relative dose to the contralateral tracts was: EC, 0.25; Fornix, 0.48; CP, 0.41; AC, 0.53; OT, 0.32; ON, 0.56. Significant reduction in ipsilateral FA of EC compared to the contralateral hemisphere was detected from the first time point of 4 weeks after radiation (4% reduction) with no significant findings in any other tracts till the 4th time point at 40 weeks, when the ipsilateral fornix also became significantly reduced in FA compared to the contralateral side (9% reduction) (Fig. 2). At the final time point of 48 weeks, there was a further marked reduction in the ipsilateral EC FA (11% reduction) and fornix FA (23% reduction). At the final time point, differences between the ipsilateral and contralateral ON became significant (5% difference) with the FA in the contralateral ON being lower than in the ipsilateral side. For the CP, AC and OT, although FA was lower in the ipsilateral tract compared to the contralateral tract, these differences did not reach statistical significance. Pathological change was first at 24 weeks after radiation with vascular dilatation observed in both the EC and the Fornix in 1 out of 4 rats examined. At 36 weeks, necrosis, vascular dilatation, white matter vacuolation, mild demyelination and axonal loss was observed in the ipsilateral EC ( $n=1/4$ ) and fornix ( $n=1/4$ ) compared to the contralateral hemisphere. Vascular dilatation was also found in the ipsilateral CP ( $n=1/4$ ) and OT ( $n=1/4$ ). While homogeneous staining of LFB and NF was observed in the ipsilateral ON, central zones of necrosis, demyelination and axonal degeneration were observed in the contralateral ON ( $n=1/4$ ), which is in keeping with reduced FA in the contralateral ON. At the 48-weeks time point, more severe necrosis, vascular dilatation, white matter vacuolation, demyelination and axonal losses were observed in the ipsilateral EC and fornix in all rats examined ( $n=7/7$ ) compared to the contralateral hemisphere. Progressed from 36-weeks time point, more severe pathological changes was observed in the contralateral ON involving more rats ( $n=4/7$ ).

**Discussion:** We found significantly reduced FA in the contralateral ON compared to the ipsilateral ON. This cannot be explained by radiation dose as the contralateral ON received lower radiation dose. We postulate this may be due to retrograde neuronal degeneration induced by higher radiation dose received by ipsilateral OT which connects to the contralateral ON as well as poor vascularisation of the ON. The findings also suggest susceptibility of the

ON compared to CP and AC. More severe changes in EC and Fornix may be explained by the higher dose they received. In conclusion, the visual pathways may be more susceptible to radiation induced injury and retrograde neuronal degeneration may be an important mechanism underlying the injury. DTI is a valuable tool in further study of radiation induced injuries.

**References:** 1. Wang S, et al. *Cancer Res* 2009;69:1190-1198. 2. Qiu D, et al. *Int J Radiat Oncol Biol Phys* 2007;69:846-851. 3. Bijl HP, et al. *Int J Radiat Oncol Biol Phys* 2005;61:543-551. 4. Lessell S. *J Neuroophthalmol* 2004;24:243-250.

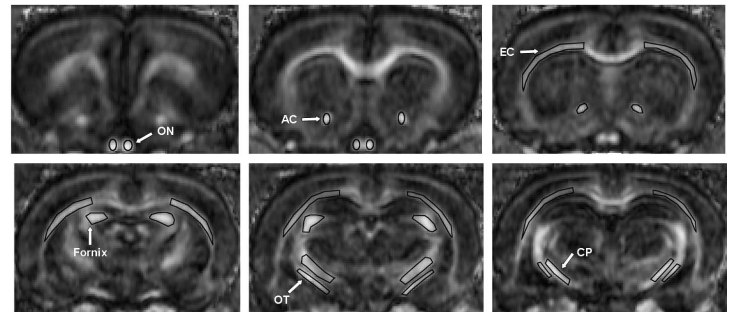


Fig. 1 shows placement of ROIs, including EC, Fornix, AC, CP, OT and ON

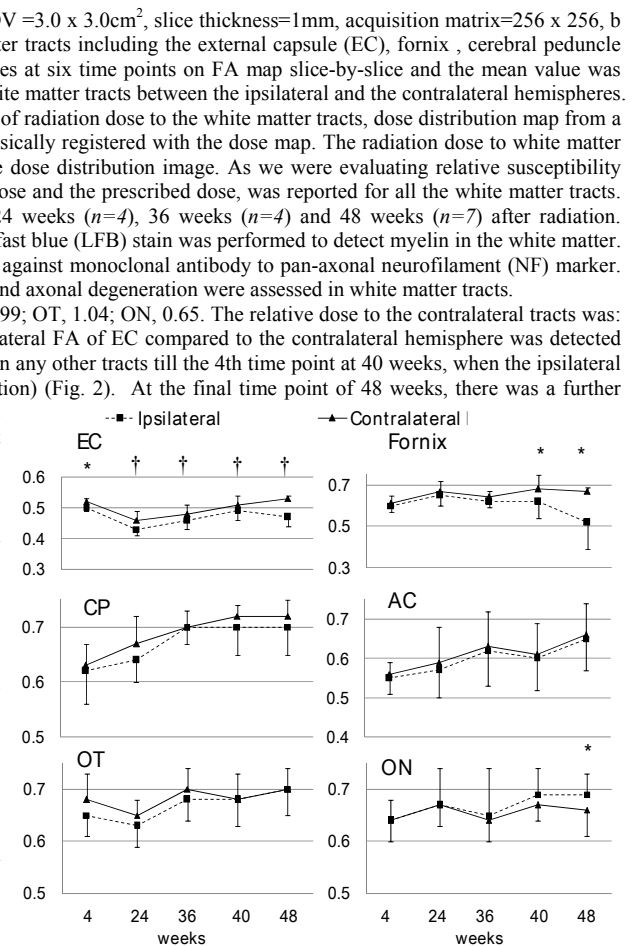


Fig. 2 shows changes of FA value in white matter tracts following radiation. \* indicates significant differences between the two hemisphere at 0.05 level, † at 0.01 level.