

Renal Perfusion and Oxygen Bioavailability in Swine: Comparing Isoflurane to Propofol

L. Dance¹, A. Wentland², N. Artz², S. Fain^{1,2}, A. Djamali³, and E. Sadowski¹

¹Radiology, University of Wisconsin, Madison, Wisconsin, United States, ²Medical Physics, University of Wisconsin, Madison, Wisconsin, United States, ³Nephrology, University of Wisconsin, Madison, Wisconsin, United States

INTRODUCTION

The drug-specific effects of anesthetics on regional perfusion are an important aspect in the design of kidney perfusion studies. Conflicting data exists in the current literature, with data in swine and dogs demonstrating no significant change in renal blood flow under inhaled isoflurane anesthesia while other data in humans, dogs, and ponies demonstrate a significant decrease in renal blood flow[1-6]. The goal of the following study was to compare the effects of propofol (PRO) vs. isoflurane (ISO) on the kidney, using arterial spin labeling (ASL) and microspheres to measure kidney perfusion and blood oxygen level dependent (BOLD) magnetic resonance (MR) imaging to measure kidney oxygen bioavailability.

MATERIALS AND METHODS

Institutional Animal Care and Use committee approval was obtained prior to this study. Seven female swine (34-38 kg) were induced with xylazine hydrochloride (2.2 mg/kg) and telazol (7 mg/kg) and maintained for the first 2 hours of the experiment with propofol (10 mg/kg/hr) and fentanyl (0.0035 mg/kg/hr). Propofol and fentanyl were stopped and isoflurane (2.75-3.5%) was used for the last two hours of the experiment. A femoral artery sheath was placed to invasively monitor the blood pressure and heart rate. Microspheres were injected after 2 hours of propofol and after 2 hours of isoflurane, via a common carotid access sheath, verified by fluoroscopy to be positioned in the left ventricle. The femoral artery sheath was used to withdraw blood during microsphere injection. After the experiment, swine were euthanized with Beuthanasia-D (0.2 ml/kg) and kidneys harvested. Blood and cortical tissue samples were sent to IMT Stason Pharmaceuticals (Irvine, CA, USA) for microsphere analysis.

Scans were performed on a 1.5 T MR scanner (GE Healthcare, Milwaukee, WI, USA) with an eight-element phased array torso coil. BOLD images were acquired with the following parameters: TR/TE/flip/BW = 87ms/7-41.8ms/40°/±62.5kHz, FOV = 32-34cm, and 256 x 128 matrix. Three coronal slices were acquired, each during a separate 12-second breath hold. ASL perfusion images were acquired in the coronal plane using a balanced SSFP 2D imaging sequence (FIESTA) with the following parameters: TR/TE/flip/BW = 4.6ms/2.3ms/70°/±41.67kHz, FOV = 34cm, 128 x 128 matrix, NEX = 1.0, slice thickness = 8mm. Non-selective and selective inversion images were alternated until 64 total images (32 pairs) were acquired. Four proton density images were also acquired for normalization purposes by using the FIESTA readout with no prior inversion pulse. MR acquisitions were performed after 2 hours of propofol and again after 2 hours of isoflurane.

BOLD images were analyzed as previously described and medullary and cortical R2* recorded[7]. ASL perfusion exams were analyzed with custom scripts written in MATLAB (MATLAB version 8.0, The MathWorks Inc., Cambridge, MA, USA). Data was analyzed using a one compartment model. Mean and standard deviations were recorded for the cortex and medulla of the kidneys. MAP, heart rate, ASL perfusion, BOLD R2*, and microsphere perfusion measurements were all compared for both time points using the paired t-test. Standard error of the mean is shown in all figures.

RESULTS AND DISCUSSION

There was a lower mean arterial pressure (MAP) [57 mmHg (ISO) vs. 93 mmHg (PRO); p=0.0002] and higher heart rate [83 bpm (ISO) vs. 69 bpm (PRO); p=0.0196] after 2 hours of isoflurane anesthesia compared to MAP and heart rate after 2 hours of propofol anesthesia. The MAP remained above 80 mmHg during propofol anesthesia in all swine (7/7), while the MAP was below 80 mmHg in most swine (6/7) during isoflurane anesthesia.

ASL perfusion measurements showed a significant decrease in cortical perfusion [104 ml/100g/min (ISO) vs. 208 ml/100g/min (PRO); p=0.0008] and medullary perfusion [42 ml/100g/min (ISO) vs. 60 ml/100g/min (PRO); p=0.004] after 2 hours of isoflurane anesthesia compared to 2 hours of propofol anesthesia. The microsphere data supported this significant decrease in cortical perfusion [162 ml/100g/min (ISO) vs. 358 ml/100g/min (PRO); p=0.0002]. BOLD MR imaging analysis demonstrated significantly higher cortical R2* measurements [12.1 s⁻¹ (ISO) vs. 9.9 s⁻¹ (PRO); p=0.021] and significantly lower medullary R2* [10.9 s⁻¹ (ISO) vs. 13.2 s⁻¹ (PRO); p=0.040] after 2 hours of isoflurane anesthesia when compared to the cortical and medullary R2* values after 2 hours of propofol anesthesia.

Our findings demonstrated a decrease in MAP and a decrease in renal perfusion and oxygen bioavailability (higher R2* values) after 2 hours of isoflurane anesthetic, compared to 2 hours of propofol anesthetic. This data supports the previous finding of decreased renal blood flow under isoflurane anesthesia[4-6]. Our findings also demonstrated higher MAP and higher renal perfusion and oxygen bioavailability with the use of propofol anesthesia, which other investigators have noted, even at propofol concentrations as high as 12 mg/kg/min[8,9].

CONCLUSIONS

Drug-specific effects on renal perfusion can be observed with ASL and BOLD MR imaging techniques. A decrease in kidney perfusion and oxygen bioavailability under isoflurane anesthesia should be considered when designing kidney perfusion studies.

REFERENCES

- [1] Lundeen *et al.* Anesth. Analg. 1983;62:499-512.
- [2] Bernard *et al.* Anesthesiology. 1991 Feb;74(2):298-302.
- [3] Merin *et al.* Anesthesiology. 1991 Mar;74(3):568-74.
- [4] Groves *et al.* Br. J. Anaesth. 1990 Dec;65(6):796-800.
- [5] Manohar *et al.* Am. J. Vet. Res. 1987 Oct;48(10):1504-10.
- [6] Hartman *et al.* Can J Anesth 1992 39(8):877-87.
- [7] Sadowski *et al.* Radiology 2005 Sep;236(3):911-9.
- [8] Shiga *et al.* Pharmacology 2003;68:17-23.
- [9] Piriou *et al.* Eur. J. Anaesth. 1999;16:615-621

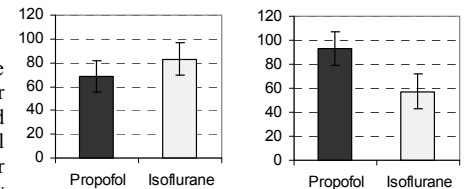


Figure 1. Average heart rate (beats/min) for all swine after two hours of propofol or isoflurane.

Figure 2. Average MAP (mmHg) for all swine after two hours of isoflurane or propofol.

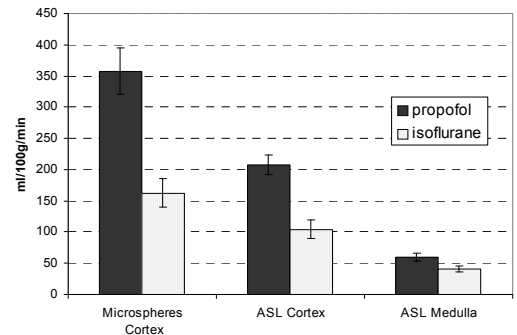


Figure 3. Average measurements of renal cortical and medullary perfusion (ml/100g/min) using ASL or microspheres are shown for all swine after two hours of isoflurane or propofol anesthesia.

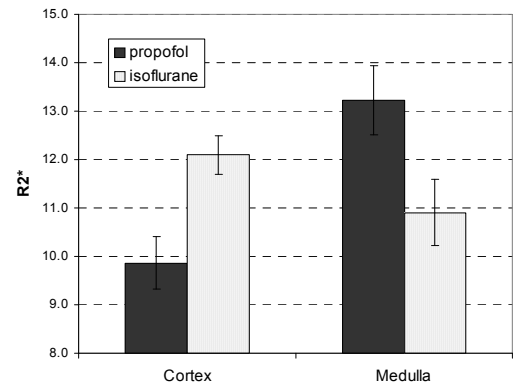


Figure 4. Average renal cortical and medullary R2* (s⁻¹) using BOLD MR imaging, after two hours of either propofol or isoflurane.