

Differentiation of benign and malignant uterine corpus tumors: value of 1H-MR spectroscopy at 3T

M. Takeuchi¹, K. Matsuzaki¹, M. Harada¹, and H. Nishitani¹

¹Department of Radiology, University of Tokushima, Tokushima, Tokushima, Japan

[Introduction] Various benign and malignant tumors in the endometrial cavity such as endometrial polyp/hyperplasia and endometrial cancer may show similar MR manifestations. Typical uterine leiomyomas show low signal intensity on T2-weighted images, however, some benign leiomyomas may show high signal intensity on T2-weighted images and to distinguish them from uterine sarcomas is often difficult. 1-H MR spectroscopy (MRS) provides metabolic information, which is useful for the differentiation of benign and malignant tumors. 3T-MRI can offer high-quality MRS due to superior spectral separation and increased signal-to-noise ratio. The purpose of this study is to verify the feasibility of MRS at 3T to differentiate benign and malignant uterine corpus tumors.

[Materials and Methods] Pathologically diagnosed 32 uterine corpus tumors including 14 malignant tumors (11 endometrial carcinomas and 3 myometrial tumors: one rhabdomyosarcoma and 2 malignant lymphoma) and 18 benign tumors (5 endometrial polyps/hyperplasia and 13 myometrial tumors: 11 leiomyomas and 2 adenomyotic lesions) were retrospectively evaluated. MRS (PRESS, TR/TE = 2000ms/144ms) was performed in all subjects on a system with a 3T superconducting units (Signa HDx 3T, General Electric, Milwaukee, WI) with 8ch body-array torso coils. Single voxel of interest (VOI=8ml) was placed on solid tumoral components for heterogeneous lesions so as not to contain cystic or necrotic areas as much as possible by referring all MR images. The choline peak (3.2ppm) was visually evaluated. Quantitative evaluation of the choline concentration was made by using LCModel (Stephen Provencher Inc.) on the workstation. Mann-Whitney's U test was used to compare the choline concentration among benign and malignant uterine corpus tumors. A value of $p < 0.05$ was considered statistically significant. The choline concentration cut off value (mM) to differentiate benign from malignant lesions was calculated, with their sensitivity, specificity, positive predictive value (PPV) and negative predictive value (NPV).

[Results] Choline peaks were observed in all 32 uterine corpus tumors, and tended to show higher peaks in malignant tumors. The choline concentration in malignancy (8.77+/-1.91 mM) was significantly higher than that in benign lesions (4.82+/-2.23 mM) ($p < 0.0001$). Using a cut off value of 7.00 mM for malignant lesions had a sensitivity of 93%, specificity of 83%, PPV of 94%, and NPV of 81%. Some benign myometrial tumors such as leiomyomas with edema or myxoid degeneration, cotyledonoid dissecting leiomyoma, polypoid adenomyoma and adenomyosis with edema showed high signal intensity on T2-weighted images mimicking uterine sarcomas, and low choline concentration suggested their benignity. Both benign endometrial polyps/hyperplasia and endometrial cancers showed high signal intensity on T2-weighted images, and quantitative evaluation of the choline concentration was helpful to distinguish benign and malignant endometrial tumors.

[Conclusions] We conclude that MRS with quantitative evaluation of the choline concentration can provide helpful information in distinguishing benign and malignant uterine corpus tumors.

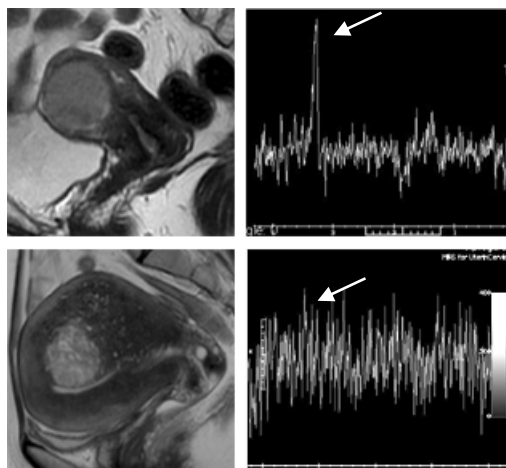
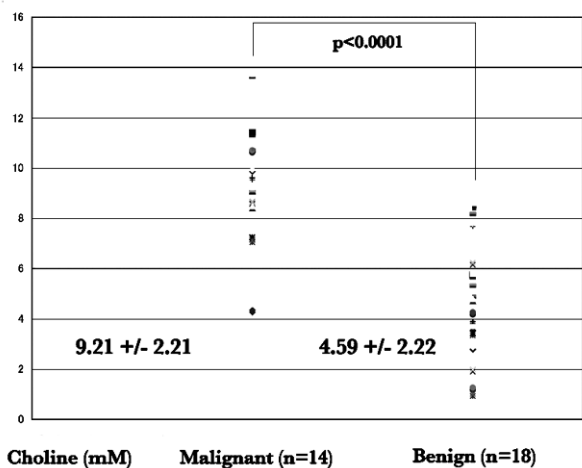


Table 1: The choline concentration in malignant and benign uterine corpus tumors.

Fig.1: Malignant lymphoma: Myometrial mass shows high intensity on T2WI, and high choline peak (8.49 mM) on MRS.

Fig.2: Adenomyosis with edema: Myometrial mass shows high intensity on T2WI, and low choline peak (1.26 mM) on MRS.

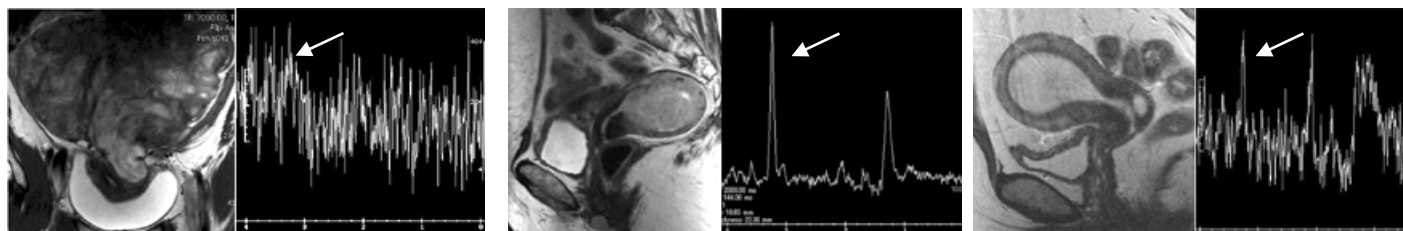


Fig.3: Subserosal polypoid adenomyoma: Huge uterine mass shows heterogeneous high intensity on T2WI mimicking uterine sarcoma, however, low choline peak (1.01 mM) on MRS suggests its benign nature.

Fig.4: Endometrial carcinoma: Endometrial mass shows high intensity on T2WI, and high choline peak (8.49 mM) on MRS.

Fig.5: Endometrial polyp: Endometrial mass shows high intensity on T2WI, and low choline peak (1.98 mM) on MRS.