

## Clinical significance of the 2 ppm resonance in in-vivo 1H-MR spectroscopy of ovarian tumors

M. Takeuchi<sup>1</sup>, K. Matsuzaki<sup>1</sup>, M. Harada<sup>1</sup>, and H. Nishitani<sup>1</sup>

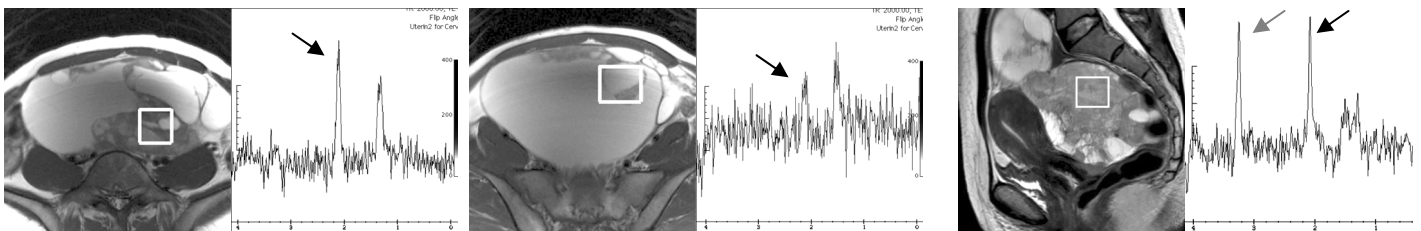
<sup>1</sup>Department of Radiology, University of Tokushima, Tokushima, Tokushima, Japan

**[Introduction]** Ovarian tumors may exhibit various morphologic appearances, and specific diagnosis on MR imaging is often difficult. 1-H MR spectroscopy (MRS) provides metabolic information, and may add valuable information for the diagnosis. The choline peak (3.2 ppm) may be observed in solid tumoral components reflecting metabolic activity of tumor cells and tend to show higher peaks in malignant tumors. However, detecting the choline concentration in the tumor may not contribute to differential diagnosis of subtypes in ovarian tumors. The peak at 2 ppm is detected in various gynecologic tumors on MRS. Boss et al. detected this peak in serous cystadenomas by ex-vivo MRS and assigned this peak as NAA (*NMR Biomed* 13, 2000). Hascalik et al. detected this peak in an ovarian mucinous cystadenoma by in-vivo MRS and assigned this peak as NAA (*Int J Gynecol Cancer* 16, 2006). However, NAA is usually present in living neurons and may be undetectable in other cell types. Lee et al. detected 2 ppm peak in 6/7 adenocarcinomas and none of 44 squamous cell carcinomas by MRS of uterine cervical cancer (*AJR* 170, 1998). Although they did not mention the subtypes of adenocarcinomas, most cervical adenocarcinomas are mucinous adenocarcinomas. Andre et al. detected 2 ppm peak mimicking NAA in sinus mucocoeles by in-vivo MRS (*AJNR* 27, 2006). They confirmed that the metabolite is not a constituent of brain NAA, and is consistent with N-acetyl mucus compounds by in-vitro MRS. In our preliminary studies, high 2 ppm peak was detected in mucinous ovarian and uterine tumors. We hypothesized that high concentration of the metabolite at 2 ppm may suggest mucinous tumors containing N-acetyl mucus compounds, and may contribute to the differential diagnosis of subtypes in ovarian tumors.

**[Materials and Methods]** Pathologically diagnosed 31 ovarian tumors including 21 malignant/borderline malignant tumors (5 endometrioid carcinomas, 4 undifferentiated carcinomas, 4 metastatic carcinomas, 3 serous adenocarcinomas, 2 mucinous tumors with borderline malignancy, one serous adenofibroma with borderline malignancy, one granulosa cell tumor and one mixed adenocarcinoma), and 10 benign tumors (6 fibroma/thecoma, 2 mucinous cystadenomas, one mucinous cystadenofibroma and one fibromatosis) were retrospectively evaluated. Among them 5 malignant tumors and 3 benign tumors were histologically revealed as mucinous tumors: 2 mucinous tumors with borderline malignancy, one mixed adenocarcinoma containing mucinous adenocarcinoma, one metastatic adenocarcinoma from gastric signet ring cell carcinoma, one metastatic adenocarcinoma from colonic mucinous adenocarcinoma, 2 mucinous cystadenomas, and one mucinous cystadenofibroma). MRS (PRESS, TR/TE = 2000ms/144ms) was performed in all subjects on a system with a 3T superconducting units (Signa HDx 3T, General Electric, Milwaukee, WI) with 8ch body-array torso coils. Single voxel of interest (VOI=8ml) was placed on solid tumoral components for heterogeneous lesions so as not to contain cystic or necrotic areas as much as possible by referring all MR images. VOI was placed on cystic area for essentially cystic lesions. The 2 ppm peak was visually evaluated (-, +/-, +, ++, +++). Quantitative evaluation of the 2 ppm concentration was made by using LCMoDel (Stephen Provencher Inc.) on the workstation. Mann-Whitney's U test was used to compare the 2 ppm concentration among mucinous tumors (n=8) and non-mucinous tumors (n=14, 9 lesions with no 2 ppm concentration were excluded from all 23 non-mucinous tumors). A value of p<0.05 was considered statistically significant. The 2 ppm concentration cut off value (mM) to differentiate mucinous from non-mucinous tumors was calculated, with their sensitivity, specificity, positive predictive value (PPV) and negative predictive value (NPV).

**[Results]** The 2 ppm peak was observed in all 8 mucinous tumors (+++, n=5; ++, n=3) (Fig. 1, 2), and 14 non-mucinous tumors (+, n=7; +/-, n=7). The 2 ppm concentration in mucinous tumors (7.39 +/- 2.85 mM) was significantly higher than that in non-mucinous lesions (3.12 +/- 1.42 mM) (p<0.005). Using a cut off value of 4.45 mM for mucinous lesions had a sensitivity of 88%, specificity of 86%, PPV of 78%, and NPV of 92%. 7 of 8 mucinous tumors were essentially cystic with/without solid components, and one metastasis from gastric cancer (Krukenberg's tumor) was a solid mass. In the Krukenberg's tumor high peaks of both choline and 2 ppm were observed (Fig. 2). All 4 serous tumors, 2 fibroma/thecoma and one endometrioid adenocarcinoma showed low 2 ppm peak (+, n=7), and 3 endometrioid adenocarcinomas, 3 undifferentiated carcinomas and one fibroma/thecoma showed slight 2 ppm peak (+/-, n=7). 4 fibroma/thecoma, two metastasis (breast cancer and urothelial cancer), one endometrioid adenocarcinoma, one undifferentiated carcinoma and one granulosa cell tumor showed no 2 ppm peak (-, n=9). In a mucinous tumor with borderline malignancy we placed two VOIs in mucinous loculus and serous loculus, and higher 2 ppm peak was detected in the mucinous loculus (Fig. 1).

**[Conclusions]** We conclude that moderate to high 2 ppm peaks may suggest the presence of mucinous material containing N-acetyl mucus compounds, and may contribute to the diagnosis of mucinous tumors. Especially, bimodal high peaks of the choline and the 2 ppm in solid mass may be characteristic for Krukenberg's tumor, and careful examination of primary gastric cancer should be made when the ovarian tumor is the first manifestation of the disease.



**Fig.1:** Mucinous tumor shows high 2 ppm peak (12.9 mM) in mucinous loculus (left), whereas low 2 ppm peak (3.7 mM) in serous loculus (right).

**Fig.2:** Krukenberg's tumor shows bimodal high peaks of choline and 2 ppm (7.05 mM).