

## DTI and 2D MR Spectroscopy of Hepatitis C in 3T

**R. Nagarajan<sup>1</sup>, M. K. Sarma<sup>1</sup>, C. Hinkin<sup>2</sup>, S. Castellon<sup>2</sup>, J. P. Smith<sup>3</sup>, H. Khanlou<sup>4</sup>, L. Bhatti<sup>4</sup>, J. Truong<sup>5</sup>, A. B. Ragin<sup>6</sup>, E. Singer<sup>7</sup>, and M. A. Thomas<sup>1</sup>**  
<sup>1</sup>Radiological Sciences, University of California Los Angeles, Los Angeles, CA, United States, <sup>2</sup>Department of Psychiatry & Biobehavioral Sciences, UCLA School of Medicine and VA Greater Los Angeles Healthcare System, Los Angeles, CA, United States, <sup>3</sup>Veteran's Affairs Greater Los Angeles Healthcare Center, <sup>4</sup>AIDS Healthcare Foundation, Westside Clinic, Los Angeles, <sup>5</sup>Kaiser Permanente, Lancaster CA, <sup>6</sup>Northwestern University, Chicago, Illinois, USA, <sup>7</sup>Neurology, UCLA School of Medicine, Los Angeles, California, United States

**Introduction:** Hepatitis is a general term that means inflammation of the liver that is often caused by infection. Hepatitis C virus (HCV) is one of the many viruses that can cause inflammation of the liver. In vivo magnetic resonance spectroscopy (MRS), and diffusion-tensor imaging (DTI) have recently opened new possibilities for noninvasively assessing the metabolic, functional, and connectivity correlates of brain metabolites and clinical disorders. Diffusion tensor imaging (DTI) is an MRI technique sensitive to the orientation of mobility in intravoxel water molecules (1, 2) and it has been widely used for studying the dependency of water proton diffusion in the brain. DTI-derived metrics, like fractional anisotropy (FA) and mean diffusivity (MD) have the potential to improve tissue characterization. The purpose of this study is to combine prior knowledge fitting (ProFit) (3) of two-dimensional (2D) localized correlated spectroscopy (L-COSY) (4) with DTI to assess the underlying changes in hepatitis C.

**Methods:** Nine hepatitis C infected patients (mean age of 56.3 years) and six healthy controls (mean age of 34.1 years) were recruited for the MRS and DTI study. All patients gave informed consent according to an institutionally approved research protocol. The following parameters were used for 2D L-COSY: TR/TE=2s/30ms, 3x3x3cm<sup>3</sup> voxel, 8 averages per  $\Delta t_1$  and 100  $\Delta t_1$  increments. The voxel was placed in the left pre-frontal lobe. The 12 channel coil was used for the hepatitis MR study. A Siemens 3T Trio-Tim MRI scanner (Siemens Medical Solutions, Erlangen, Germany) was used and DTI was performed using a single-shot multi-section spin-echo echo-planar pulse sequence [repetition time (TR) = 9600 ms; echo-time (TE) = 90 ms; average = 1] in the axial plane, with a 130 × 130 matrix size, 256 × 256 mm<sup>2</sup> field of view (FOV), 2.0 mm slice thickness, 72 slices. For each slice, diffusion gradients were applied along 64 independent orientations with b = 1000 sec/mm<sup>2</sup> after the acquisition of b = 0 sec/mm<sup>2</sup> (b0) images.

**Results and Discussion:** The ProFit algorithm was used to process 2D L-COSY to quantify the following metabolites: (N-acetylaspartate (NAA), creatine (Cr), glycerylphosphocholine (GPC), phosphorylcholine (PCh), free choline (Cho), alanine (Ala), aspartate (Asp), gamma-aminobutyric acid (GABA), glucose (Glc), glutamine (Gln), glutamate (Glu), glycine (Gly), glutathione (GSH), lactate (Lac), myo-inositol (ml), acetylaspartylglutamate (NAAG), phosphoethanolamine (PE), taurine (Tau), scyllo-inositol (Scy) and ascorbate (Asc). Fig.1. shows aspartate changes with respect to creatine (Asp/Cr) in the left frontal white matter. The aspartate ratio was significantly elevated in patients affected by hepatitis C compared to healthy controls (p= 0.002). There were no significant changes observed in other cerebral metabolite ratios. DTI data was processed using DTI studio; and region of interest (ROI) analysis was done on MD and FA map using ImageJ. The MD and FA values in the left frontal locations are shown in Table 1. Patients with hepatitis C showed significantly increased values of MD (p= 0.012) compared to healthy controls in the frontal white, but the FA changes were not significant. The changes in Asp/Cr were positively correlated with MD values of hepatitis C patients.

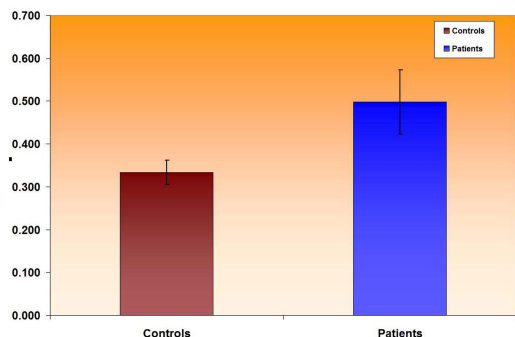


Fig.1. Aspartate to creatine ratios for HCV+ patients vs. healthy controls

Frontal left location	Patients (Mean ± SD)	Controls (Mean ± SD)	p value
Mean Diffusivity (x10 <sup>-3</sup> mm <sup>2</sup> /s)	0.847±0.053	0.774±0.037	0.012
Fractional Anisotropy	0.353±0.040	0.376±0.012	0.539

Table 1. MD and FA values (Mean ± SD) processed by ROI analysis

**Conclusion:** Magnetic resonance spectroscopy and DTI are complementary modalities for the study of patients with hepatitis C. While conventional MRI did not reveal any significant changes in the frontal white matter of hepatitis C patients, DTI and 2D L-COSY were shown to be sensitive to HCV-associated neurophysiologic changes. These findings underscore the utility of DTI and MRS in study of HCV associated neurological disorder.

**Acknowledgement:** This research was supported by National Institute of Mental Health (NIMH) grant MH083553.

### References

1. Bassar PJ, Mattiello J, LeBihan D. Biophys J. 1994; 66: 259–267.
2. Beaulieu C. NMR Biomed. 2002; 15: 435–455.
3. E. Frias-Martinez, Rajakumar N, Liu X, et al. ISMRM 2008; Pp 691.
4. Thomas MA, Yue K, Binesh N, et al. Magn. Reson. Med. 2001; 46: 58-67.