

MEASUREMENTS OF THE ABDOMINAL FAT AREA: COMPARISON WITH MR AND CT MEASUREMENTS IN MEDICAL CHECK-UPS

T. Masui¹, M. Katayama¹, R. Takafuji², T. Natume¹, S. Nozawa², H. Ikuma¹, K. Sato¹, K. Asano³, H. A. Haque³, M. Sugimura¹, S. Imamura², and A. Nozaki³
¹Radiology, Seirei Hamamatsu General Hospital, Hamamatsu, Japan, ²Seirei Kenshin Center, Hamamatsu, Japan, ³GEHC-Japan, Hino, Japan

INTRODUCTION: Metabolic syndrome might be related to accumulation of fat contents in the abdomen and may cause various diseases. An increase of intra-abdominal fat is regarded as a main risk factor of metabolic and cardiovascular diseases. So far, as one of the criteria for metabolic syndrome, measurements of intra-abdominal fat area using CT have been suggested. CT measurement of abdominal fat is accurate but also delivers ionizing radiation exposure. MR imaging can provide a noninvasive way of assessing fat without ionizing radiation exposure. However, for replacing CT measurements by MR measurement using T1WI, or T2WI, there are some obstacles to be overcome. Firstly, there is no absolute value for SNR to demarcate subcutaneous and visceral fat. Secondly, inhomogeneous signal intensities through field of view are observed with phased array coils and even with a body coil. Thirdly, the boundaries between fat and other soft tissues are not always clear since signal intensities gradually change over the fat tissue and other soft tissues. Multi-echo with 2-point Dixon reconstruction for decomposition aqua/lipid (MEDAL or LAVA flex, GEHC, Milwaukee) can provide in-phase, opposed phase, fat and water images and, modification of these images can be utilized to set the threshold to determine the boundary between the fat and other soft tissue, and semiautomatic demarcation of the subcutaneous and visceral fat might be performed. Accordingly, the purposes of this study were to apply semiautomatic demarcation of the fat areas on MR data and to evaluate correlations between MR and CT measurements for the quantitative assessment of subcutaneous and visceral fat in subjects who underwent medical check-ups.

METHODS: A total of 160 subjects were included, who underwent both MR and CT for the evaluation of the visceral and subcutaneous fat areas in medical check ups. Institutional review board approved the study and written informed consent was obtained from all the subjects. All MR examinations were performed on a 1.5-T system (HDxt; GE Healthcare, Milwaukee, Wis), using an eight channel body array coil. In-phase images, opposed phase images, water images, and fat images were obtained with MEDAL (TR /TE msec, 6.3/2.3, 4.6; matrix, 256x192; acquisition time, 24seconds; section thickness, 5mm; no gap). All CT examinations were performed on a ProSpeedF II (GE HC). Both MR and CT images in a transverse plane were obtained at the umbilical level. *MR evaluation:* Fat fraction images were calculated by using equation of SNR on fat /SNR on fat+water images and threshold value for background and fat was set at 15% and 60%, respectively. With semiautomatic drawing with manual correction for boundaries, visceral and subcutaneous fat areas were calculated. *CT evaluations:* Semiautomatic calculation software (FatScan) was used for visceral and subcutaneous fat area, which has been approved to be accurate. Correlation between MR and CT measurements was evaluated using linear regression analysis.

RESULTS: Good correlation between MR and CT measurements was observed in 160 subjects in visceral fat area [MR $91.3\text{cm}^2 \pm 40.1$ (mean \pm standard deviation) cm^2 , CT $88.0 \pm 40.6 \text{cm}^2$ ($r=0.911$, $p<0.0001$, 95%CI: 0.943, 0.969)] and in subcutaneous fat area [(MR $140.1 \pm 49.8 \text{cm}^2$, CT $139.3 \pm 52.0 \text{cm}^2$ ($r=0.913$, $p<0.0001$, 95%CI: 0.940, 0.967)].

SUMMARY AND CONCLUSION: Good correlation was observed between MR and CT measurements of visceral and subcutaneous fat area. Fat images and in-phase images could be utilized to provide relatively stable threshold to demarcate fat and other soft tissues. Without stable separation of the fat and water images using LAVA Flex, demarcation of the fat and other soft tissues might be difficult. On the other hand, on CT, demarcation of fat and other soft tissues might not be difficult since fat tissue has relatively specific CT numbers. Imaging time of 24 seconds for LAVA flex is acceptable. And CT measurement of abdominal fat, which is regarded as an established method can be replaced by MR without ionizing radiation exposure in the relatively large population for medical checkups.

Fig.1

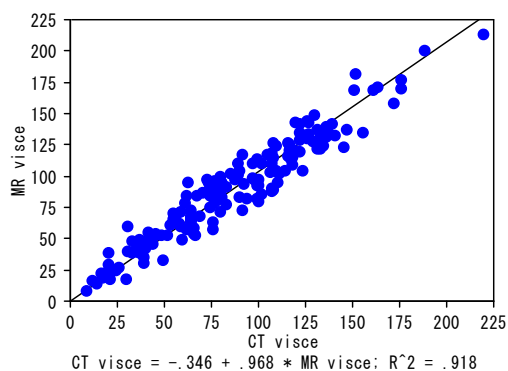


Fig.2

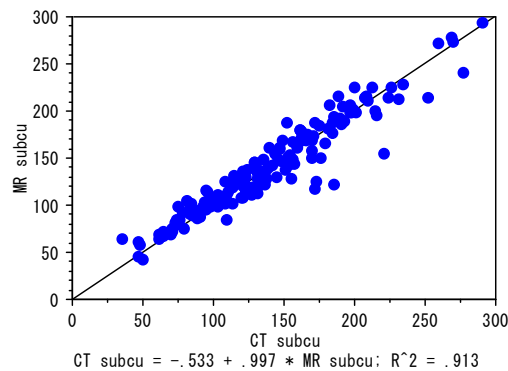


Fig.1: Correlation between MR and CT measurements of visceral fat area.

Fig.2: Correlation between MR and CT measurements of subcutaneous fat area.