

Reproducibility of MRI-Determined Proton Density Fat Fraction (PDFF) across MR Scanner Platforms and Field Strength

G. H. Kang¹, M. Schroeder¹, M. Shiehorteza¹, B. Johnson¹, T. Wolfson¹, A. Gamst¹, G. Hamilton¹, M. Bydder¹, T. Yokoo¹, and C. Sirlin¹

¹Radiology, University of California, San Diego, San Diego, CA, United States

Introduction: As a result of the growing epidemic of obesity in adults and children, fatty liver disease (FLD) has become the most common liver condition in the United States. [1] FLD contributes to the development of cardiovascular disease and type II diabetes and it may progress to cirrhosis and hepatocellular carcinoma. [2] The current clinical gold standard for diagnosis and monitoring of FLD is liver biopsy. Because of its invasiveness, liver biopsy is suboptimal for screening and repeated measurements. These limitations have hampered progress in clinical care and research in FLD. Thus, there is an increasing clinical and research need for a noninvasive fat quantification technique. While conventional MR imaging is often used to detect liver fat, it is rendered inaccurate for quantifications by the confounding effects of relaxation and multi-peak spectral interference. [3,4] To address these confounders, new T1-independent, T2*-corrected, spectral modeled chemical shift based fat quantification techniques have been developed. These techniques can be implemented using either magnitude or complex data and permit estimation of the proton density fat fraction (PDFF), the fraction of mobile protons in liver tissue attributable to fat. In prior studies, these techniques have shown high accuracy for fat quantification using MR spectroscopy (MRS) as the reference standard. [5] To our knowledge, all prior studies have been single field strength studies performed on a single MRI platform. In order to be accepted as a clinical and research biomarker, the use of MRI-determined PDFF needs to be further validated. Confirmation that MRI-determined PDFF is independent of field strength and MR scanner is an important step in validation. The primary purpose of this study was to evaluate the reproducibility of MRI-determined PDFF across field strengths and MR scanner platforms. The secondary purpose was to evaluate the accuracy of MRI-determined PDFF using MRS-determined PDFF as the reference standard. In this study we utilized a magnitude based MRI sequence that can be implemented easily on different scanner platforms.

Materials and Methods: In this HIPAA-compliant, IRB-approved prospective clinical study, 30 human subjects (16 men, 15 women; median age, 31 years; range, 10-63 years) were enrolled after giving informed consent. All participants underwent MR imaging of the liver at both 1.5T (Siemens Symphony scanner) and 3T (GE Signa scanner). 24 subjects had MRS at 1.5T and 24 subjects at 3T (20 had MRS at both 1.5T and 3T). 1.5T and 3T MR examinations were performed on the same day in random order. MRI-determined PDFF was estimated using a 2D axial GRE imaging sequence with low flip-angle to minimize T1 effects and multiple echo-times to permit T2* correction. The applied imaging parameters at each scanner are summarized in **Table 1**. MRS-determined PDFF was estimated using a single-voxel STEAM sequence with long repetition time to minimize T1 effects and multiple echo-times to permit T2 correction. Using a Picture Archiving and Communication System (PACS), three circular regions of interest (ROIs), approximately 400 mm², were manually placed on one of the multi-echo images. The first ROI was colocalized to the 1.5T MRS voxel. The second ROI was colocalized to the 3T MRS voxel. A third separate ROI was placed in the right hepatic lobe away from either MRS voxel location. The selected ROIs were automatically propagated to the rest of the multi-echo images. The average ROI value at each TE was recorded. MRI-determined PDFF was calculated from T2*-corrected fat and water signals using a 5-peak fat spectral model (0.9, 1.3, 2.1, 4.2, 5.3 ppm) with normalized weights (0.05, 0.04, 0.12, 0.70, 0.09) derived from human MR spectra with known and suspected fatty liver. MRS-determined PDFF was calculated from T2-corrected peak areas of water and fat. Linear regression analysis between 3T and 1.5T PDFF estimates was computed using all three ROIs. A mixed-effects version of a paired Student t-test was used to assess systematic shifts between 3T and 1.5T PDFF. The accuracy of MRI-determined PDFF was evaluated, using MRS-determined PDFF as the reference standard, separately at each field strength by linear regression correlation and paired Student t-tests; the MRI data from the ROI colocalized to the MRS voxel at each field strength was used in the analysis of accuracy.

Table 1: Imaging Parameters of MRI Scanners

	1.5T	3T
TR (msec)	120-150	125-240
dTE (msec)	2.3	1.15
FA	10	10
ST (mm)	8	8
GAP	0	0

TR: Relaxation Time; dTE: Echo Spacing; FA: Flip Angle; ST: Slice Thickness

Results: Based on MRS, the population sample had mean PDFF of 15.0% (range 0.1-38.8%). At least 4 subjects had PDFF in each of the following ranges: 0-5%, 6-10%, 11-15%, 16-20% and >21%. The linear regression analysis (**Figure. 1**) compares the PDFF at 1.5 and 3.0T, where the diagonal line represents equality in PDFF calculated from 1.5T and 3T MR imaging. The differences between the 1.5T and 3T PDFF estimates were minimal (regression slope 0.991, regression intercept 0.861%) but statistically significant. (P<0.001 for both parameters). Using MRS data as a reference standard, MRI-determined PDFF had high accuracy. The regression slope between MRI- and MRS-determined PDFF was 0.99 at both 1.5T and 3T (**Figures 2 and 3**), with the MRI-determined PDFF estimates consistently higher than MRS-determined PDFF estimates by 1.07% (p <0.0001) at 1.5T (**Figure.2**) and lower by 1.24% (p = 0.007) at 3T (**Figure.3**).

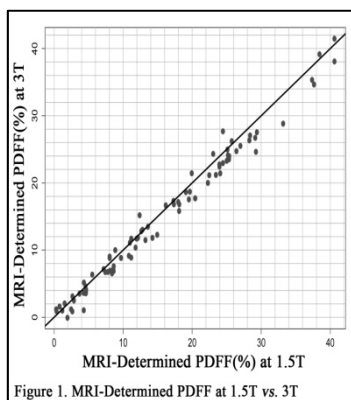


Figure 1. MRI-Determined PDFF at 1.5T vs. 3T

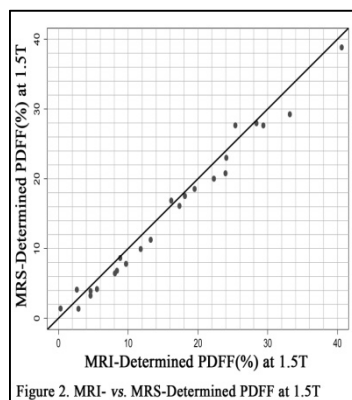


Figure 2. MRI- vs. MRS-Determined PDFF at 1.5T

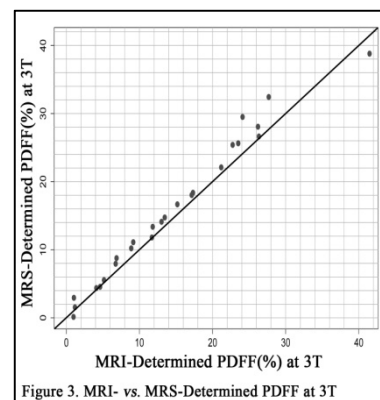


Figure 3. MRI- vs. MRS-Determined PDFF at 3T

Conclusion: MRI-determined PDFF quantification is reproducible across field strengths and MR scanner platforms and shows high accuracy using MRS-determined PDFF as the reference standard.

References:

- [1] Agrawal, S, et al. Management of nonalcoholic steatohepatitis: an analytic review. *J Clin Gastroenterology*. 35(3): 253-61.
- [2] Neuschwander-Tetri, BA, et al. Nonalcoholic steatohepatitis: summary of an AASLD Single Topic Conference. *Hepatology*. 37(5): 1202-19.
- [3] Bydder M, et al. Relaxation effects in the quantification of fat using gradient echo imaging. *Magn Reson Imaging*. 2008; 26(3):347-59.
- [4] Reeder SB, et al. T1 independent, T2* corrected MRI with accurate spectral modeling for quantification of fat: validation in a fat-water-SPIO phantom. *J Magn Reson Imaging*. 2009 Nov;30(5):1215-22.
- [5] Yokoo T, et al. Nonalcoholic fatty liver disease: diagnostic and fat-grading accuracy of low-flip-angle multiecho gradient-recalled-echo MR imaging at 1.5 T. *Radiology*. 2009 Apr;251(1):67-76.