

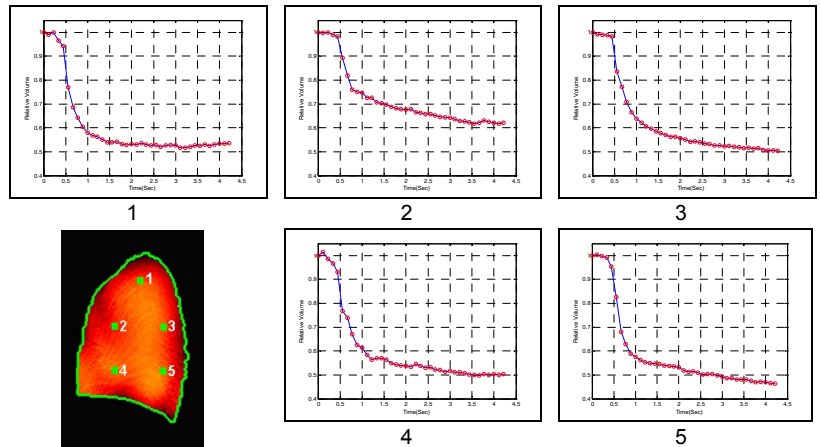
# MRI Assessment of Distal Airway Heterogeneity for the Early Detection of Airway Disease with Normal Spirometry

D. Xia<sup>1</sup>, E. J. Grossman<sup>1</sup>, K. Zhang<sup>1</sup>, A. Voorhees<sup>2</sup>, K. I. Berger<sup>3</sup>, R. M. Goldring<sup>3</sup>, B. W. Oppenheimer<sup>3</sup>, J. Reibman<sup>3</sup>, W. N. Rom<sup>3</sup>, L. Rogers<sup>3</sup>, A. Helwig<sup>3</sup>, L. Daugherty<sup>4</sup>, J. Xu<sup>1</sup>, K. A. McGorty<sup>1</sup>, and Q. Chen<sup>1</sup>

<sup>1</sup>Center for Biomedical Imaging, Department of Radiology, NYU School of Medicine, New York, New York, United States, <sup>2</sup>Siemens Medical Solutions, Malvern, Pennsylvania, United States, <sup>3</sup>Department of Medicine, NYU School of Medicine, New York, New York, United States, <sup>4</sup>Department of Radiology, University of Pennsylvania, Philadelphia, Pennsylvania, United States

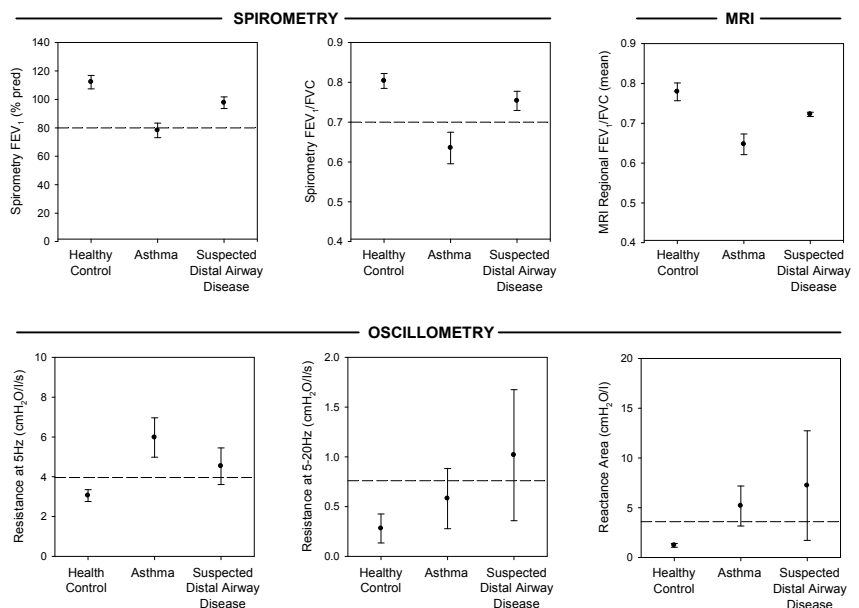
**Introduction:** When airway abnormalities are localized only to the distal airways clinical-pathologic correlation between patient illness and lung disease has been difficult to establish. This study establishes quantitative, regional measurements of heterogeneity for distal airway dysfunction based on a tissue tracking MRI technique and applies the technique to the early diagnosis of obstructive airway disease by correlation with physiologic markers of distal airway dysfunction.

**Methods:** Ten subjects were studied: normal controls (n=3), asthmatics (n=4), and individuals with suspected isolated distal airway dysfunction (n=3) due to either toxic dust exposure and/or cigarette smoking. The study was IRB approved and all participants provided proper informed written consent. Spirometry and impulse oscillometry (IOS) were obtained from all subjects. MRI data were acquired on a Siemens 3T whole-body MR scanner (Magnetom TIM Trio) using a tissue-tracking MRI technique that has been previously described [1]. Measurements were made in sagittal imaging planes and were acquired in real-time at rates up to 10 frames per second (fps). Subjects were instructed to take a series of normal tidal breaths followed by maximal inspiration and maximal forced expiration. This procedure was specifically chosen because airway collapse and distal airway dysfunction are most likely to be elicited during maximal effort when intrathoracic pressure is markedly positive. Pixel displacements were estimated using an optical flow method by comparing sequential images during exhalation [2]. Sequential displacements were used to calculate the change in volume (3 x 3 pixel region) to produce local volume vs. time curves (Figure 1). FEV<sub>1</sub>/FVC was determined for each region and a histogram was constructed [1]. The mean value ± SD of the regional FEV<sub>1</sub>/FVC histogram was used as an MRI derived metric of distal airway function. Data were compared with IOS derived resistance at 5Hz (R5), and distal airway heterogeneity was assessed by frequency dependence of resistance from 5-20Hz (R5-20) and reactance area (Ax).



**Figure 1.** Changes in lung volume relative to end-inspiratory volume vs. time for selected regions (1-5) during forced expiration.

**Results:** Data summarizing results for spirometry, MRI, and oscillometry are shown in Figure 2. Spirometry demonstrated airflow obstruction in subjects with asthma (FEV<sub>1</sub> 78 ± 5 % pred, FEV<sub>1</sub>/FVC 0.64 ± 0.04) but was normal in subjects with distal airway disease (FEV<sub>1</sub> = 98 ± 4 % pred, FEV<sub>1</sub>/FVC = 0.75 ± 0.02). MRI assessment of regional lung function showed a reduction in the mean value for regional FEV<sub>1</sub>/FVC in subjects with asthma as compared with healthy controls, consistent with known obstructive disease (0.65 ± .03 vs. 0.78 ± .02, respectively). In subjects with suspected distal airway disease the MRI mean regional FEV<sub>1</sub>/FVC was also reduced (0.72 ± .01) despite the normal large airway function as assessed by spirometry. IOS data are shown in the bottom panels. Mean values for IOS parameters were abnormal in the subjects with suspected distal airway disease, which differed from normal controls and were similar to subjects with asthma. Thus, MRI demonstrated regional changes of lung function in subjects with suspected distal airway disease that were associated with abnormalities in distal airway mechanics as assessed by oscillometry.



**Figure 2:** Spirometry, MRI, and oscillometry data for three subject groups. The dashed lines represent the normal limits for each parameter.

**Conclusions:** Heterogeneity of distal airway function determined by MRI is tightly linked to heterogeneity of distal airway mechanics determined by IOS. The data confirm presence of distal airway dysfunction in subjects with suspected distal airway disease, which was not apparent on standard spirometry. Thus, assessment of regional lung function by MRI may be a useful tool for early detection of airway disease.

**Acknowledgements:** This work was supported in part by NIH grant R01 HL069023.

**References:** 1. Zhang K, et al. Assessing local lung function: measurement of regional FEV<sub>1</sub>/FVC using tissue tracking MRI. Proc ISMRM 16, 2008:3787. 2. Xu C, et al. Utility of the optical flow method for motion tracking in the lung. Proc ISMRM 16, 2008:2638.