

### **3D Hyperpolarized $^3\text{He}$ Imaging of Human Lung with Isotropic Spatial Resolution Using 3D-Cones**

J.-X. WANG<sup>1</sup>, A. V. Ouriadov<sup>2</sup>, J. A. Stainsby<sup>3</sup>, G. E. Parraga<sup>2</sup>, and G. Santyr<sup>2,4</sup>

<sup>1</sup>Applied Science Laboratory, GE HEALTHCARE, London, ON, Canada, <sup>2</sup>Robarts Research Institute, The University of Western Ontario, London, ON, Canada,

<sup>3</sup>Applied Science Laboratory, GE HEALTHCARE, Toronto, ON, Canada, <sup>4</sup>Dept. of Medical Biophysics, The University of Western Ontario, London, ON, Canada

#### **Introduction:**

Hyperpolarized  $^3\text{He}$  MRI with 3D isotropic resolution is desirable for detection of lung structures and ventilation defects [1]. The 3D-Cones pulse sequence [2] provides efficient, uniform, 3D sampling for isotropic spatial resolution for hyperpolarized  $^3\text{He}$  human lung imaging and may have additional advantages over conventional methods, because it is less sensitive to signal attenuation from both short  $T_2^*$  in the lung and  $^3\text{He}$  diffusion-weighting. The objective of this work was to develop and test a 3D-Cones pulse sequence in healthy volunteers and compare to standard gradient-echo imaging.

#### **Methods:**

$^3\text{He}$  MR imaging was performed on a GE 3T MR750 scanner (GEHC, Waukesha, WI). Hyperpolarized  $^3\text{He}$  (polarization  $\sim 35\%$ ) was provided by a turn-key, spin-exchange polarizing system (HeliSpin<sup>TM</sup>, GEHC). Healthy human volunteers were imaged using a protocol approved by the UWO Standing Committee on Human Research Ethics. A 3D-Cones imaging sequence was used with hard pulse width = 3ms, TR/TE=9.0/0.1ms, FOV=40cm, 4 mm isotropic resolution and 1000 points per cone trajectory. A Variable Flip Angle (VFA) acquisition method was used [3]. 3D-Cones image data-sets were acquired during a 16-second breath-hold. Extra points were acquired before the gradient waveform. During the reconstruction, the centre of k-space was found by shifting the start point of the readout data to correct the gradient delay time.

#### **Results:**

Fig. 1 shows a representative set of axial and coronal Cones images of the lung. The entire lung can be visualized in detail. With 4mm isotropic resolution and 40cm of FOV, the 16 seconds breath hold time was safe and well-tolerated at our site. The signal to noise ratio (SNR) is sufficient to sample lung structures and ventilation defects.

**Discussion:** The 3D-Cones sequence provides lung images with isotropic spatial resolution with excellent image quality. The relatively short breath-hold interval (16s) may be useful for respiratory compromised subjects. By combining two-echo times,  $T_2^*$  mapping is also feasible with 40cm FOV and 8mm isotropic resolution within the breath-hold. The isotropic voxel size should improve accuracy for co-registration, lung volume measurement and analysis of ventilation defects in subjects with chronic obstructive pulmonary disease (COPD).

#### **Acknowledgement:**

The authors thank C. Harper-Little, S. Halko, S. McKay and members of the London Lung Imaging Team for their assistance with the human lung studies.

#### **References:**

[1] J. H. Holmes et al, MRM 59 (2008) 1062–1071; [2] PT Gurney et al., MRM, 2006, 55(3): 575-582;

[3] G Santyr et al. MRM 59:1304–1310, 2008

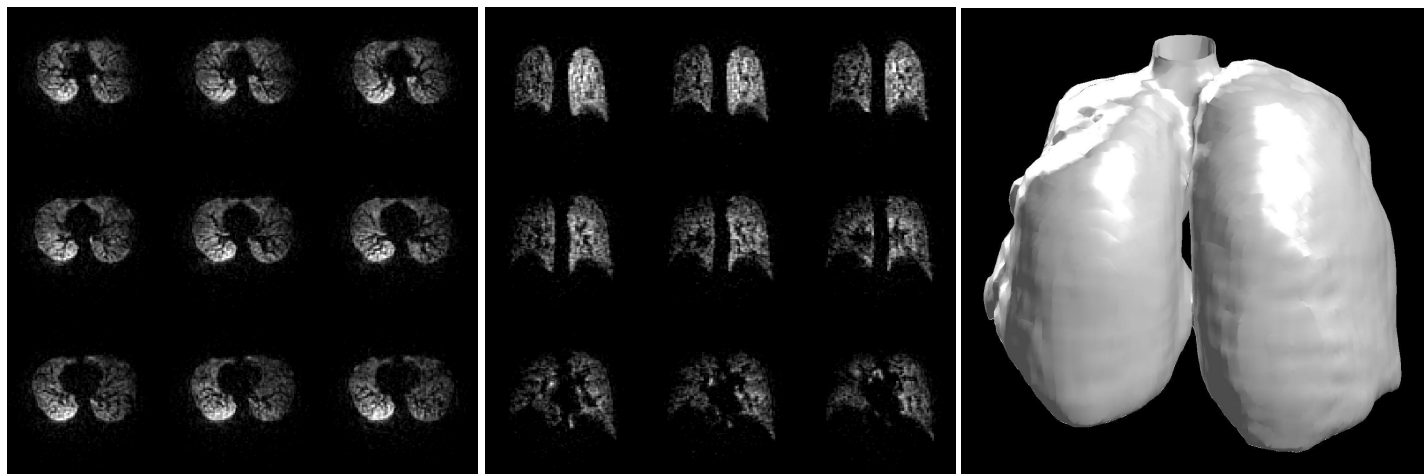


Fig. 1. Representative slices of a 40cm FOV 3D lung images with 4mm isotropic spatial resolution. Left: axial view; Center: coronal view; Right: surface-rendered image.