

# Time-Resolved MR Angiography in the Detection of Ovarian Venous Reflux

D. Yang<sup>1</sup>, D. Lee<sup>2</sup>, D. Sung<sup>2</sup>, G-H. Jahng<sup>3</sup>, and C. Ryu<sup>3</sup>

<sup>1</sup>Radiology, East-West Neo Medical Center, Kyung Hee University, Seoul, Korea, Republic of, <sup>2</sup>Radiology, Kyung Hee University Hospital, <sup>3</sup>Radiology, East-West Neo Medical Center, Kyung Hee University

## Introduction

Chronic pelvic pain is a common health problem among women that is characterized by non-cyclic pelvic pain for more than 6 months in duration. It has been reported that as many as 39.1% of women had chronic pelvic pain at some time their lives. Pelvic congestion syndrome is defined as chronic pelvic pain caused by incompetent ovarian veins, which associated venous reflux and venous engorgement. For the detection of pelvic congestion syndrome, conventional angiography is currently considered the gold standard. However, this procedure is time-consuming, invasive, and necessitates the use of ionizing radiation. Several noninvasive techniques are used for workup of pelvic venous congestion, including ultrasound, CT, MRI. Time-resolved MR angiography has been proven to be a quick and noninvasive technique that allows evaluation of the physiologic blood flow. The purpose of this study was to compare the diagnostic accuracy of time-resolved MR angiography with that of conventional angiography for detection of ovarian venous reflux, which aid for a diagnosis of pelvic venous congestion.

## Materials and Methods

Retrospective analysis was performed with 19 consecutive patients who underwent time-resolved MR angiography and conventional angiography. Time-resolved MR angiography and conventional angiography images were interpreted in consensus by two radiologists. MR imaging was performed on a 1.5 T system (Achieva 1.5 T, Philips Systems, Best, The Netherlands). Time-resolved MR angiography was acquired using contrast-enhanced timing robust angiography (CENTRA) keyhole technique. The acquisition parameters of the time-resolved MR angiography were the following: TR/TE = 5.5/1.5 msec, flip angle = 35°, matrix = 300 x 200, slices/slab = 70, slice thickness = 1.6 mm, FOV = 35-40 cm. Four phases of imaging of the pelvis was performed in the coronal plane after IV injection of 0.1 mmol/kg body weight of contrast media at a rate of 2 mL/s. Maximum intensity projection of each 3D data set were generated in the coronal plane. The grades of reflux were divided into three grades. Grade 1 reflux means the reflux confines in the left ovarian vein. Grade 2 reflux means that the reflux advanced into the ipsilateral parauterine veins. Grade 3 reflux means that the retrograde flow crossed the midline passing the uterus from the left into the right parauterine plexus. Maximal diameters of left ovarian veins and left parauterine veins were measured. The McNemar test was performed to determine the significance of any differences found.

## Results

There was no significant difference between time-resolved MR angiography and conventional angiography for detection of ovarian venous reflux ( $P > 0.05$ ). The sensitivity, specificity, and diagnostic accuracy of time-resolved MR angiography were found to be 93.5%, 66.7%, and 89.5%, respectively. The mean diameter of the left renal vein was  $6.9 \pm 1.3$  mm (range, 4.1-9.7 mm) on time-resolved MR angiography and  $8.1 \pm 1.1$  mm (range, 5.6-10.5 mm) on conventional angiography.

## Discussions

The findings of the present study that time-resolved MR angiography is almost equal to conventional angiography in the detection of ovarian venous reflux and time-resolved MR angiography is well-suited as screening method in the initial evaluation of patients with suspected pelvic venous congestion.

## References

1. Hiromura T, Nishioka T, Nishioka S, et al. AJR 2004 ;183 :1411-1415
2. Kim HS, Malhotra AD, Rowe PC, et al. J Vas Interv Radiol 2006 ;17 :289-297
3. Ascuitto G, Mumme A, Marpe B, et al. Eur J Vasc Endovasc Surg 2008 ;36 :491-496

Table 1. Comparison Between Time-resolved MRA and Conventional Angiography

MRA	Conventional Angiography		
	Grade 1	Grade 2	Grade 3
Grade 1	2	1	0
Grade 2	1	10	1
Grade 3	0	0	4

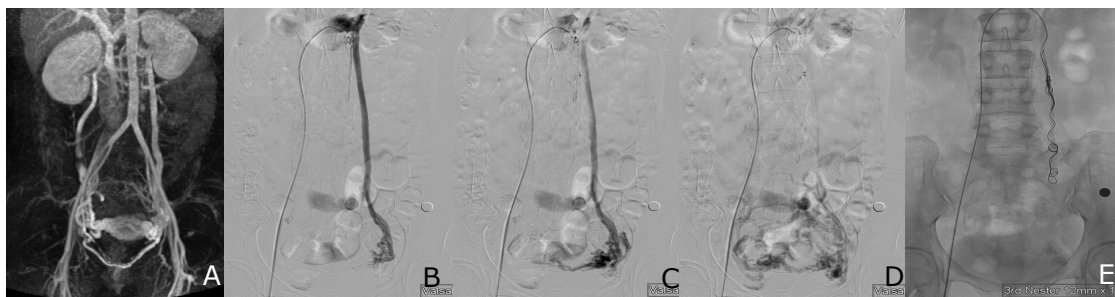


Fig 1. A 45-year-old woman with chronic pelvic pain. A, Coronal MIP image obtained during early venous phase shows dilatation of both uterine vein and both parauterine veins due to reflux (Grade 3). B-D, Selective left renal venography with Valsalva maneuver shows a dilated left ovarian vein and left parauterine veins. The right ovarian vein and right parauterine veins are dilated due to the retrograde flow crossed the midline passing the uterus from the left into the right parauterine plexus. E, Transcatheter embolization of the left ovarian vein using multiple coils was performed.