

MRI Findings of Triple Negative Breast Cancer: A Comparison with Non Triple Negative Breast Cancer

J. Choi¹, S. Kim¹, E. Cha², H. Kim³, J. Byun¹, B. Kang¹, and J. Lee¹

¹Radiology, Seoul St. Mary's Hospital, Catholic University of Korea, Seoul, Seoul, Korea, Republic of, ²Radiology, St. Vincent's Hospital, Catholic University of Korea, Seoul, Seoul, Korea, Republic of, ³Radiology, St. Paul's Hospital, Catholic University of Korea, Seoul, Seoul, Korea, Republic of

Purpose:

To evaluate the magnetic resonance imaging (MRI) and clinicopathologic features of triple negative breast cancer, and compared them with those of non triple negative breast cancer.

Materials and Methods:

This study included pathologically confirmed 231 breast cancers (triple negative breast cancers (n=43), non triple negative breast cancers (n=188)) between 2007 and 2008. The MRI findings were reviewed according to the Breast Imaging Reporting and Data System (BI-RADS) lexicon; mass or non mass type, mass shape, mass margin, non mass distribution, and enhancement pattern. Available mammographic findings, histologic grade, epidermal growth factor receptor, p53, Ki 67 results were reviewed. We compared imaging features and clinicopathological findings of triple negative breast cancers with those of non triple negative breast cancers.

Results:

Lobular mass shape (p=0.006) and rim enhancement (p=0.004) on MRI were significantly associated with triple negative breast cancer. There was no significant difference in mammographic findings in two groups. Old age (p=0.019), high histologic grade (p<0.0001), EGFR positivity (p<0.0001), p53 overexpression (p=0.038) and Ki 67 expression (<0.0001) were significantly associated with triple negative breast cancer.

Conclusion:

Knowledge of several MRI findings may be helpful to diagnosis triple negative breast cancer.

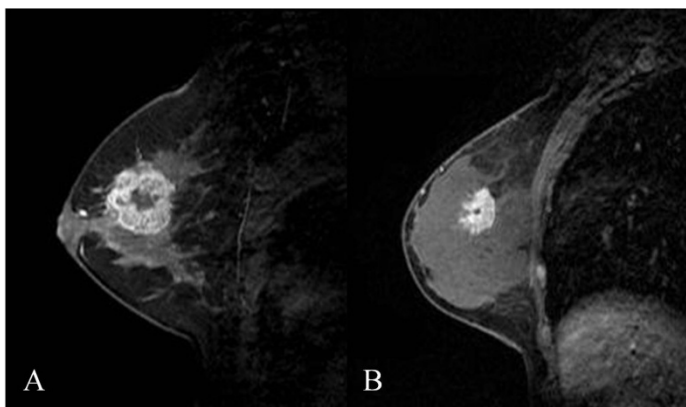


Figure. MRI findings of a Triple Negative Breast Cancer (A) and a Non Triple Negative Breast Cancer (B). Triple negative breast cancer showed mass with lobular shape, smooth margin and rim enhancement. Non triple negative breast cancer showed irregular mass with spiculated margin.

References:

1. Uematsu, T., M. Kasami, and S. Yuen, Triple-negative breast cancer: correlation between MR imaging and pathologic findings. *Radiology*, 2009. 250(3): p. 638-47.
2. Chen, J.H., et al., Triple-negative breast cancer: MRI features in 29 patients. *Ann Oncol*, 2007. 18(12): p. 2042-3.
3. Yang, W.T., et al., Mammographic features of triple receptor-negative primary breast cancers in young premenopausal women. *Breast Cancer Res Treat*, 2008. 111(3): p. 405-10.
4. Reis-Filho, J.S. and A.N. Tutt, Triple negative tumours: a critical review. *Histopathology*, 2008. 52(1): p. 108-18.

MRI findings	Triple Negative Breast Cancer (n=43)	Non Triple Negative Breast Cancer (n=188)	P value
Lesion Type			
Mass	40 (93.0%)	152 (80.9%)	0.055
Non mass	3 (7.0%)	36 (19.2%)	
Mass shape			
Round/oval	16 (40.0%)	41(27.0%)	0.006
Lobular	17(42.5%)	42(27.6%)	
Irregular	7 (17.5%)	69 (45.4%)	
Mass margin			
Smooth	15 (37.5%)	35 (23.0%)	0.032
Irregular	20 (50.0%)	69 (45.4%)	
Spiculated	5 (12.5%)	48 (31.6%)	
Mass enhancement			
Homogeneous	2 (5.0%)	10 (6.7%)	0.004
Heterogeneous	13 (32.5%)	91 (59.9%)	
Rim	25 (62.5%)	51 (33.6%)	
Non mass distribution			
Focal	1 (33.3%)	5 (13.9%)	0.614
Segmental	2 (66.7%)	28 (77.8%)	
Regional	0	3 (8.3%)	
Non mass enhancement			
Homogeneous	0	5 (13.9%)	0.765
Heterogeneous	1 (33.3%)	15 (41.7%)	
Stippled or punctuate	0	2 (5.6%)	
Clumped	2 (66.7%)	14 (38.9%)	

Table. MRI findings of Triple Negative Breast Cancers and Non Triple Negative Breast Cancers.