

Lateralisation of Perisylvian Pathways with Age in Asperger's Syndrome – a cross-sectional DTI study

S. Budisavljevic¹, F. Dell'Acqua², S. Forkel³, M. Thiebaut de Schotten³, and M. Catani³

¹Department of Forensic and Neurodevelopmental Sciences, Institute of Psychiatry, King's College, London, United Kingdom,

²Department of Forensic and Neurodevelopmental Sciences, Institute of Psychiatry, King's College, London, ³Department of Forensic and Neurodevelopmental Sciences, Institute of Psychiatry, King's College

Background

Abnormalities in cortical long-range connectivity and white matter enlargement during brain maturation may underlie some of the deficits observed in autism spectrum disorders (Herbert et al. 2004). In particular children with autism and language impairment have reversed asymmetry in frontal language-related cortex (De Fosse et al. 2004). The arcuate fasciculus connects perisylvian fronto-parietal-temporal areas, which have been demonstrated to be involved in theory of mind, language and social cognition. This perisylvian network is also thought to overlap with the mirror neuron system (Frith & Frith 2006).

Objectives

To investigate age-related changes in the lateralization pattern of perisylvian pathways in people with Asperger's syndrome using diffusion tensor imaging tractography.

Methods

We recruited 83 subjects: 61 healthy controls and 22 subjects with Asperger's Syndrome diagnosed according to the ICD-10 criteria. The 22 subjects with Asperger's Syndrome (mean age 24.3±13.2) and 61 age- and gender-matched controls (mean age 26.3±10.6) were investigated with DT-MRI tractography. Tract-specific measurements of number of streamlines (SL) were acquired in both hemispheres for the arcuate fasciculus and for each of its segments. A lateralization index was calculated for each segment by counting the number of streamlines in both hemispheres (LI = difference between left and right hemispheres / average number of streamlines in each hemisphere).

Results

Correlation of lateralisation index with age between groups differed significantly for the posterior indirect pathway: it was symmetrical at all ages for people with Asperger's syndrome but controls developed rightward lateralisation with increasing age. No significant differences were found for the anterior and the long segment.

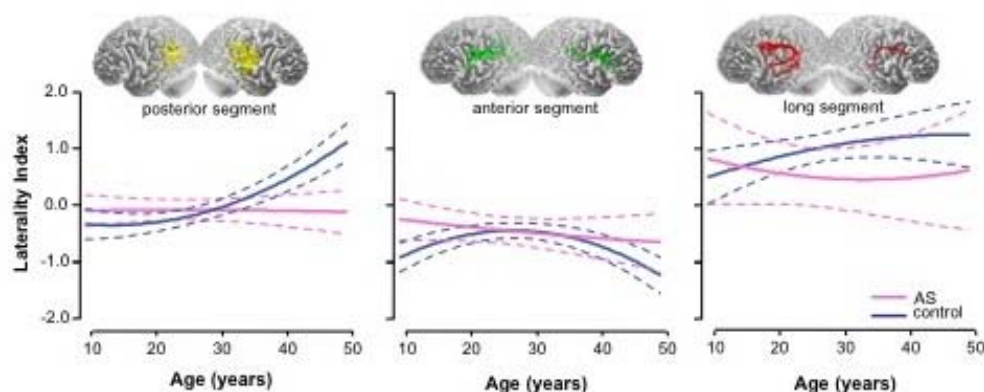


Fig. 1. Age-related changes in the pattern of lateralization for the posterior, anterior, and long segments of the arcuate bundle (quadratic fit lines \pm mean 95% confidence intervals). Differences between Asperger's subjects and controls are significant for the posterior segment ($Z_{\text{obs}}=2.46$).

Conclusion

The indirect pathway of the arcuate fasciculus shows abnormal development with age in people with Asperger's syndrome. This suggests that abnormalities in white matter development may be a key feature of autism spectrum disorders and may explain impairments in language and communication.