

# Retinotopy extension in primary visual cortex associated with perimetry improvement in a case of hemianopia after visual restoration therapy

Y-C. L. Ho<sup>1,2</sup>, A. Cheze<sup>2</sup>, E. T. Petersen<sup>2,3</sup>, A. Gjedde<sup>1,4</sup>, K-Y. Goh<sup>5</sup>, Y-Y. Sitoh<sup>2</sup>, and X. Golay<sup>2,6</sup>

<sup>1</sup>CFIN, University of Aarhus, Aarhus, Denmark, <sup>2</sup>Neuroradiology, National Neuroscience Institute, Singapore, Singapore, <sup>3</sup>Clinical Imaging Research Centre, NUS, Singapore, <sup>4</sup>University of Copenhagen, Denmark, <sup>5</sup>Eye Institute, Tan Tock Seng Hospital, Singapore, <sup>6</sup>Institute of Neurology, UCL, London, United Kingdom

**INTRODUCTION:** Though rare, it appears that visual field defects due to lesions in or near the occipital cortex may undergo recovery [1-2]. One example is with Visual Restoration Therapy (VRT) [3], which seems to reduce the visual scotomata of patients with post-chiasmatal lesions through repetitive training [2-3]. Increased BOLD activity associated with attentional processes has been found after such training [4]. However, no clear anatomical or physiological basis has been given for the apparent visual field enlargement in patients. Based on fMRI retinotopic mapping, we assessed a patient before and after VRT. Prior to therapy, the patient was found to have residual neurovascular function and limited retinotopic organization around the lesion despite his dense hemianopia [5]. We report the post therapy results here.

**METHODS:** The patient had a complete homonymous hemianopia (Figs 1, 2a, 3a) due to a right posterior cerebral artery ischemic stroke 1 year prior to therapy. Foveal vision and colour perception was preserved. He was assessed with informed consent before, midway and after therapy, which lasted 9 months. Humphrey automated visual fields analysis was performed each time, together with high resolution perimetry using the VRT setup. *Retinotopic mapping:* Angular retinotopic mapping was performed within the MRI scanner (visual angle: 30° horizontal, 25° vertical). Alertness and central fixation was maintained with a fixation task. *MRI:* A Philips clinical 3.0T imager with SENSE was used. fMRI parameters: TR/TE = 2000/30 ms,  $\alpha = 90^\circ$ , FOV = 224x224 mm, matrix = 112x112, slices = 30, slice thickness = 4 mm, gap = 0 mm, scan time = 10 m 40 s. *Data Analysis:* BOLD-fMRI data were corrected for motion, slice timing and low frequency drifts with no spatial smoothing (BV QX v.2.). Cross correlations ( $r \geq 0.3$ ,  $p < 0.002$ , corr.) were performed to create the retinotopic maps. Cortical images were segmented and computationally “inflated”, with the retinotopic maps coregistered to them. *Controls.* Five healthy volunteers (3 M, 2 F; 27 – 57 years) were scanned with the same protocol twice each about 2 weeks apart to assess reliability.

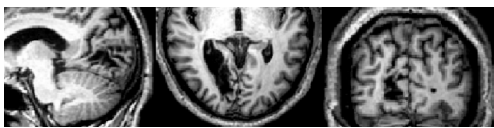

Fig. 1: The patient’s right occipital lobe infarct.

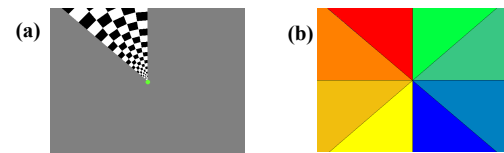


Fig. 4: (a) Angular retinotopic mapping paradigm: reversing checkerboard wedge moved anti-clockwise through 8 positions for 4 cycles. (b) Colour legend for fMRI activations corresponding to the various positions of the rotating wedge.

Fig. 2: Humphrey visual field analysis showing the dense hemianopia (a) before therapy, and (b) after therapy, focusing on the fovea.

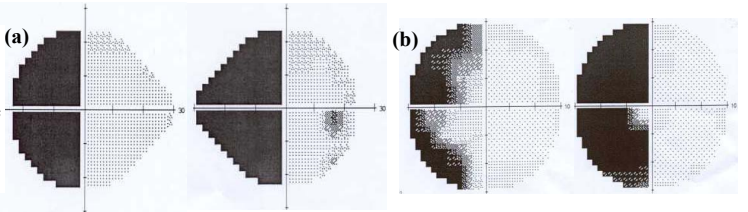
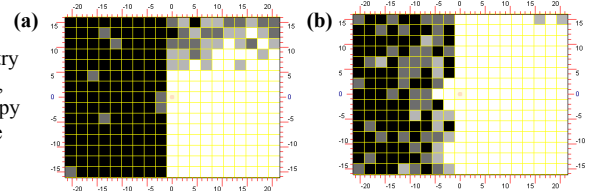


Fig. 3: High resolution perimetry (a) before therapy, and (b) after therapy showing moderate improvement.



**RESULTS & DISCUSSION:** Retinotopic mapping performed on healthy volunteers showed reproducibility across time. Prior to therapy the patient showed residual extrastriate retinotopic representation around the infarcted area (Fig 5a), suggesting surviving cortex that might respond to therapy [5]. Scans done midway through treatment unfortunately had to be disregarded due to excessive movement artefacts. Post therapy, the fMRI results showed a small but clear enlargement of the retinotopic representation around the lesion, in and superior to the calcarine sulcus (Fig 5b), supporting the moderate improvement in the high resolution perimetry results  $\pm 4^\circ$  (Fig 2b), in line with the original reports of the method [2]. For this case, assuming tight neurovascular coupling, there was enhancement of the residual retinotopic representation in primary visual cortex that seemed to be associated with therapy. To our knowledge, this is the first study on apparent recovery of retinotopic representation in the primary visual cortex via ad hoc treatment of patients with visual field deficits, in particular with VRT. It supports a potential mechanistic explanation for reduced scotomata with VRT. In addition to harnessing “top-down” attentional processes [4], the directed and repetitive stimulation in the blind field may also trigger a “bottom-up” process, whereby neurons adjacent to the lesion may become more responsive to previously subthreshold inputs [6]. If the optic radiation is assumed to be dysfunctional, another possible processing and recovery route could be via extrastriate ‘blindsight’ pathways [7,8], with the implication that partially restored visual representation may not always result in conscious visual perception.

## REFERENCES:

- [1] Seghier ML, '05, BMC Neurol 5, 17.
- [2] Kastner E, '99, Restor Neurol Neurosci 15(2-3):273
- [3] Kastner E, '98, Nature Med 4: 1083
- [4] Marshall RS, '08, Neurorehabil Neural Repair 22(2):136
- [5] Ho Y-C, '09, AAMS 38(9):827
- [6] Eysel '99, Cereb Cortex 9:101
- [7] Cowey A, '91, TINS 14(4):140
- [8] Sahraie A, '06, PNAS 103(40):14971

**Acknowledgements:** SMF and SHF/FG121S/2005.

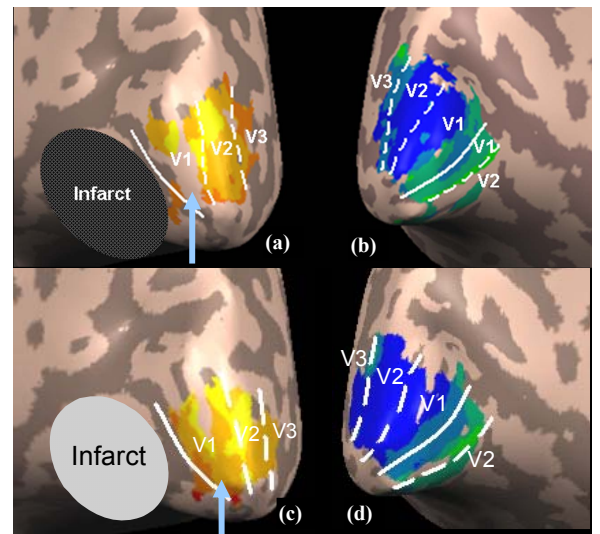


Fig. 5: Before therapy: (a) Inflated cortex showing the retinotopic organisation. Solid white line is the calcarine sulcus while the broken lines represent the visual area boundaries. Arrow shows ‘hole’ in activation. (b) Inflated cortex of left hemisphere showing normal retinotopic organisation. After therapy: (c) Arrow shows activation of V1 superior to infarct, closing up part of the previous hole. (d) Normal left hemisphere has no significant change in retinotopic organisation.