

Comparison of Cortical Stimulation and fMRI for Language and Motor Localization in Pediatric Patients

A. Poliakov¹, D. Shaw¹, H. Shurtleff², M. Warner², R. Saneto³, J. Kuratani³, E. Novotny⁴, and J. Ojemann⁵

¹Radiology, Seattle Children's Hospital, Seattle, WA, United States, ²Neurology, Seattle Children's Hospital, Seattle, WA, United States, ³Clinical&Translational Science, Seattle Children's Hospital, Seattle, WA, United States, ⁴Neurology, Seattle Children's Hospital, ⁵Neurological Surgery, Seattle Children's Hospital, Seattle, WA, United States

Introduction Accurate localization of language, motor and other cortical areas is essential for surgical planning in pediatric patients with intractable epilepsy. It is generally accepted that atypical language patterns may be present in children with early seizure onset due to cortical reorganization and malformations of cortical development as a cause of their epilepsy. Electrical Stimulation Mapping (ESM), though quite invasive, has long been the gold standard for functional mapping of eloquent cortex including sensory-motor and language areas. Functional MRI (fMRI) is evolving as a non-invasive tool for functional brain mapping in clinical applications. In particular, fMRI is proving to be a reliable tool for identifying sensory-motor cortex, and language lateralization and localization primarily in adult patients. We wished to review our experience comparing fMRI to ESM in pediatric patients.

Methods We identified five pediatric patients (age 6-11) who underwent ESM and fMRI studies as a part of their pre-surgical resection evaluation within the last year. Patients were implanted with a combination of intracranial 64-electrode grid, strip and depth electrodes. Motor and language mapping was performed using bipolar stimulation during object naming. Escalating current intensity, 1 to 10 mA, was used to trigger motor activation or functional alteration in language. fMRI tasks included (1) silent verb generation from pictures and words, and (2) finger to thumb tapping. Patients rehearsed tasks extensively and practiced holding still. fMRI data acquisition was performed on Siemens (Erlangen, Germany) system, 3T scanners, using EPIBOLD sequence (TE=30ms, TR=3000ms, flip angle = 90°). Data analysis was performed using Siemens software as well as FSL and MRICron software packages.

Results *Motor:* In all five cases results of ESM were found to be in good agreement with fMRI results. *Language:* Two patients had the grid implanted on the side believed to be contralateral to language-essential areas, including one with apparent right dominant language lateralization based on fMRI. ESM stimulation concordantly found no contralateral language. Three other patients had the grid overlaying language essential areas. In one patient (Fig. 1) a language essential site was found to closely agree with fMRI findings. In a second patient, stimulation of areas implicated with fMRI were found to induce seizure activity, therefore it was not feasible to study language in these areas using ESM. The final patient demonstrated diffuse activation with poor localization on fMRI and similarly no clear localization with ESM.

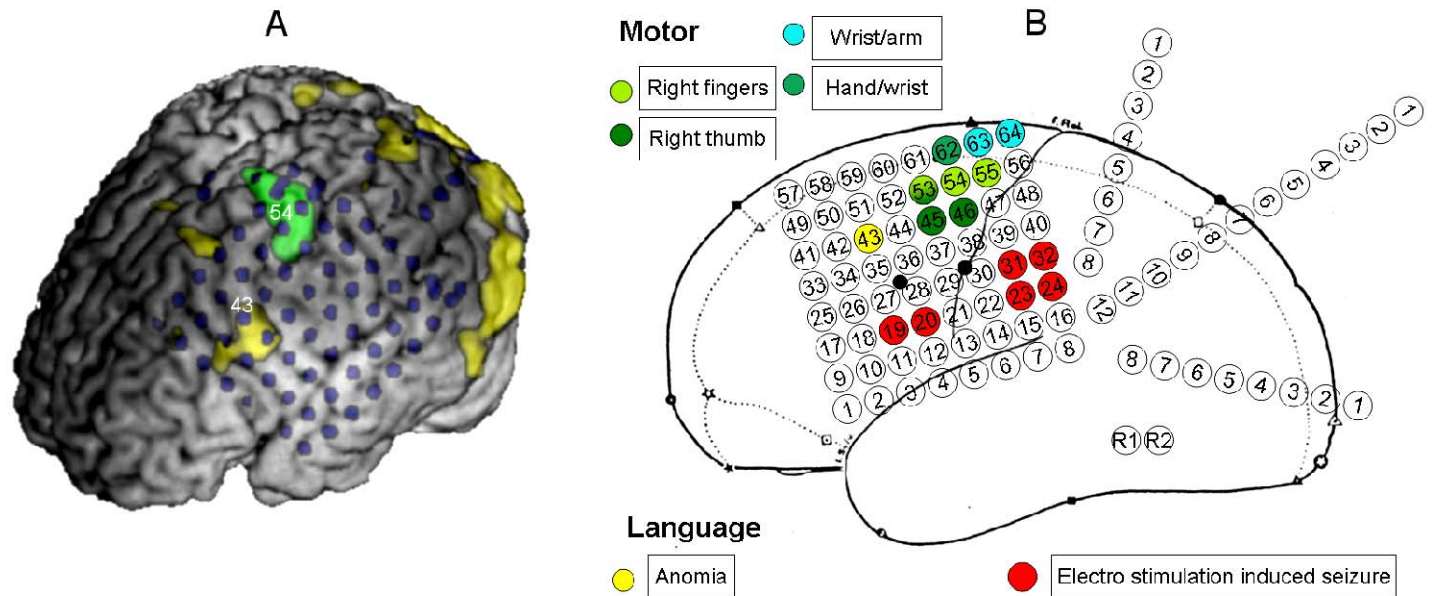


Figure 1 Co-localization of language and motor areas in one patient. **A** Motor (green) and Language (yellow) fMRI activation is overlaid onto the rendering of patient's brain, along with CT (blue) showing the grid and strip electrodes. **B** Summary of ESM report. Stimulation of site 43 was found to consistently disrupt language producing anomia. Sites 45, 46, 53-55 and 62-64 caused movements in the right hand and arm.

Conclusion Pediatric patients present a particular challenge for brain mapping; employment of multiple techniques for cortical mapping would be expected to improve pre-surgical evaluation. In this limited series, fMRI motor mapping correlated well with ESM. Language lateralization also correlated with ESM in cases which were evaluable. ESM evaluation of eloquent cortex is limited in areas where stimulation induces seizures; suggesting a potential utility of fMRI as a complementary technique.