

Multimodality Study for Restless Legs Syndrome Revealed Local Morphological Changes Associated with T2: Hypomyelination or Iron Deficiency?

B.-Y. Lee¹, J. R. Connor², and Q. X. Yang^{1,3}

¹Bioengineering, Penn State Hershey Medical Center, Hershey, PA, United States, ²Neurosurgery, Penn State Hershey Medical Center, Hershey, PA, United States, ³Radiology, Penn State Hershey Medical Center, Hershey, PA, United States

Introduction:

Restless leg syndrome (RLS) is a sensory-motor disorder characterized by uncontrollable urges to move the legs, causing chronic sleep disturbances. Brain iron deficiency has been considered as an important contributing factor to RLS [1-2]. In this study, we applied voxel-based relaxometry (VBR) for in vivo iron measurement and voxel-based morphometry (VBM) for morphological study respectively to a same study cohort, aiming to determine the impact of iron deficiency on brain morphology. Our results revealed a striking association of local T2 change with brain atrophy.

Methods:

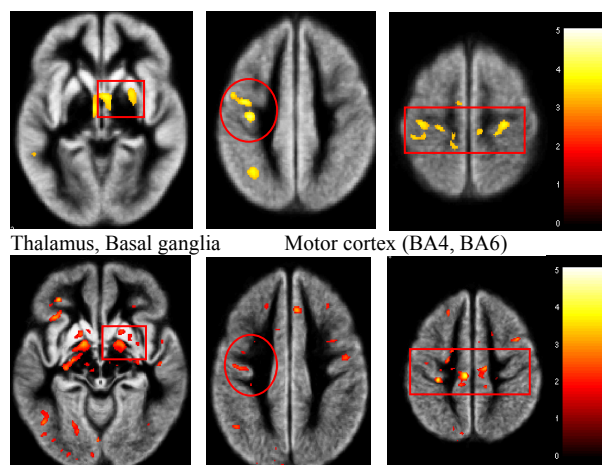
Subjects: 30 patients with RLS (54.5±14.3 yrs) and 36 age- and gender-matched controls (51.8±14.6 yrs) were studied. The RLS severity (mean 24.4±6.9, severe status) was evaluated by using in IRLSSG [3]. To minimize drug effects on structural changes, all patients discontinued RLS medication for at least one week prior to MR scanning.

MR data acquisition: All image data were acquired on 3.0 T whole-body system (Philips Medical). For volumetric analysis, high resolution T1-weighted images (MP-RAGE, TR/TE/TI=9.9/4.6/600ms, matrix size=256×256, slice thickness=1mm) were acquired. For VBR analysis, a turbo spin echo (TSE) was used due to echo dependence of echo time on the iron contents of brain tissues. A series of T₂-weighted images were obtained employing 14 equidistant echoes of 8ms (TR = 3792ms, acquisition matrix = 256×256, slice thickness = 4mm, FOV=23×23cm, acquisition time = 6 minutes 50s).

Data processing & Statistics: For VBM analysis, high resolution T1 images were segmented into GM/WM/CSF with tissue probability maps using VBM5 toolbox [4]. After segmentation, the final tissue map of GM was modulated with the Jacobian matrix to analyze volume differences between study populations. Finally, the modulated tissue maps were smoothed with an isotropic 8 mm FWHM Gaussian kernel. For VBR analysis, R2 (1/T2) maps were generated by self-built software QMRI. Spatial normalization was achieved by registration of each R2 map into the Montreal Neurological Institute (MNI) space using the new created R2 template. Subsequently, registered images with transformed volumes were resampled by trilinear interpolation to a final voxel size of 0.9×0.9×2 mm. Finally, the spatially normalized images were smoothed with an 2.5×2.5×5mm FWHM Gaussian kernel. For statistical group comparison between RLS and control group, an analysis of covariance (ANCOVA) was used with an age covariate. A significance level was set at corrected $p < 0.05$ (cluster level) for multiple comparisons. In this study, much care was taken to avoid any possible confounding factors such as age and gender in order to explore the subtle pathological changes of RLS.

Results and Discussion:

Using the same cohort of subjects, we revealed a significant decreases in both volume and R2 within the same general brain regions, including the subcortical regions (thalamus, basal ganglia) as well as motor cortex areas (Brodmann area (BA) 4, BA 6) (Figs. 1-2). Previous observation of R2 decrease in the basal ganglia was attributed to iron deficiency. The R2 change observed here in the motor area is unlikely the case, since unlike basal ganglia and substantial nigra, motor brain regions in gray matter do not have focal higher iron concentration than surrounding tissues. It is more likely that lower R2 values in RLS may also be attributed by hypomyelination as revealed by a recent study of brain protein analysis [5]. It is plausible that this could explain the observed atrophic changes in the same brain regions. Our multimodality MRI data provide an important link in characterization and understanding of the pathogenesis of RLS. In addition, the multimodality approach could provide a more specific and sensitive imaging marker for evaluation of RLS.



Decreases in volumetric (Fig 1, top) and R2 values (Fig 2, bottom) in the sensory-motor pathway of RLS patients, including subcortical region (thalamus, basal ganglia), and motor cortex region (BA4, BA6). Statistical results were displayed on the gray matter template at threshold corrected $p < 0.05$. Color bar shows T score values. BA: Brodmann's area, BA 4, Primary motor cortex; BA 6, Pre- and supplementary motor cortex

References:

- [1]. Ekbom KA, 1960. Neurology 10, 868-873
- [2]. Connor *et al.*, 2003. Neurology 61, 304-309
- [3]. Water TC *et al.*, 2004. Sleep Med. 5, 406-411
- [4]. VBM5, <http://dbm.neuro.uni-jena.de/vbm/vbm5-for-spm5>
- [5]. Lee *et al.*, 2009. Proc. Intl. Soc. Mag. Reson. Med. 17, 243

Acknowledgement:

Grants from NIH 1R01AG027771-01A2 and PA Department of Health SAP 4100039920