

# IN VIVO VASCULAR HALLMARKS OF DIFFUSE LEUKOARAIOSIS

J. Uh<sup>1</sup>, U. Yezhuvath<sup>1</sup>, Y. Cheng<sup>1</sup>, and H. Lu<sup>1</sup>

<sup>1</sup>Advanced Imaging Research Center, University of Texas Southwestern Medical Center, Dallas, Texas, United States

**INTRODUCTION:** The physiologic mechanisms of leukoaraiosis are not well understood and the clinical consequences are not yet clear. Pathologic studies of leukoaraiosis tissue have shown that the leukoaraiosis regions are characterized by arteriosclerosis and thickening of vascular wall as well as narrowing of vessel lumen (1), suggesting an origin of vascular ischemia. Others have postulated that leukoaraiosis is caused by the toxicity of serum protein when leaked into the extravascular tissue (2), as supported by observations of plasma proteins in leukoaraiosis tissue (3). Testing of these hypotheses in vivo has previously been difficult due to two possible reasons: 1) White matter intrinsically has very few blood vessels, thus the assessment of vascular parameters is challenging and often suffers from low signal-to-noise ratio (SNR); 2) Diffuse leukoaraiosis lesions are small and the spatial resolution of the imaging modality needs to be sufficiently high in order to avoid partial volume effect from surrounding normal tissue. Recent advances in high-field MR systems as well as the development of novel MR sequences have allowed the specific mapping of various physiologic parameters in the brain. In the present work, we conduct a multi-parametric assessment of tissue and vascular properties to gain a better understanding of physiologic hallmarks in leukoaraiosis in normal elderly subjects.

**METHODS:** Twenty three normal elderly volunteers (age 74.4±5.7years, 14 males) were studied on a 3T system (Philips Achieva) after consent was obtained. Leukoaraiosis was assessed by hyperintense signals in FLAIR MRI (resolution = 0.45×0.45mm<sup>2</sup>, number of slices = 24, thickness = 5mm). Three vascular parameters were measured. Baseline cerebral blood flow (CBF) and cerebrovascular reactivity (CVR) were determined in 10 subjects. Blood-brain-barrier (BBB) permeability was assessed in another group of 13 subjects. CBF was measured using a Pseudo-Continuous-Arterial-Spin-Labeling (PCASL) technique (4). CVR was assessed by measurement of BOLD MRI signal before and during inhalation of 5% CO<sub>2</sub> (mixed with 21% O<sub>2</sub> and 74% N<sub>2</sub>), following a previous technical study (5). The linear regression between the EtCO<sub>2</sub> trace and the BOLD signal time-course gives CVR map in unit of %BOLD/mmHg EtCO<sub>2</sub>. BBB permeability was assessed by a contrast-enhanced Vascular-Space-Occupancy (VASO) technique (6), which has been previously used to study BBB permeability in different grades of glioma (7). The scan protocol included a pre-contrast scan, injection of contrast agent (Magnevist®, dosage=0.1 mmol/kg), and a post-contrast scan. The VASO signal difference between pre- and post-contrast images, ΔVASO, was obtained in terms of percentage (%) of equilibrium magnetization (6). ΔVASO reflects a combined effect of cerebral blood volume (CBV) and BBB leakage. To separate these two components, the CBV effect was estimated from the group-averaged CBF data using the well-known CBV/CBF relationship (8),  $CBV = CBF^{0.38}$ . Then, the BBB leakage,  $K_{BBB}$ , was calculated by  $K_{BBB} = \Delta VASO_L - \Delta VASO_N \cdot (CBV_L / CBV_N)^{0.38}$ , where the subscripts L and N denote values in leukoaraiosis and normal appearing white matter (NAWM), respectively. In addition to the vascular images, diffusion tensor image (DTI) and T1w image (MPRAGE) were acquired for structural analysis and image registration. The images from the vascular scans and DTI were spatially co-registered to FLAIR images so that the vascular and structural parameters in leukoaraiosis and NAWM are calculated.

**RESULTS and DISCUSSION:** The CBF values in leukoaraiosis and NAWM regions were 12.6±7.3 (N=10) and 20.2±6.5 ml/min/100 ml brain, respectively. Paired t-test revealed a reduction of 38±30% (p=0.01) in CBF, suggesting a possible vascular deficit in the leukoaraiosis regions. However, CBF itself is not sufficient to determine the causality of the mechanism in that either neuron-initiated (as in brain activation) or vasculature-initiated (as in ischemia) processes can result in a CBF change. We therefore also assessed CVR, which is expected to specifically reflect the vascular health status in terms of endothelium and smooth muscle functions. CVR demonstrated a 48±37% deficit (N=10, p=0.005) in vasodilatory capacity in leukoaraiosis regions (0.035±0.037 and 0.066±0.013 %BOLD/mmHg for leukoaraiosis and NAWM, respectively).  $K_{BBB}$  in leukoaraiosis was found to be 0.27±0.42 %. This is significantly greater than 0 (p=0.04, N=13), suggesting that white matter in leukoaraiosis has BBB leakage. Interestingly, both BBB and vascular reserve are associated with endothelium function, suggesting a central role of vascular endothelium in the formation of leukoaraiosis, consistent with recent hypothesis of O'Sullivan and colleagues (9). We further tested the hypothesized that subjects with severe leukoaraiosis would have greater BBB leakage (i.e. larger  $K_{BBB}$ ) using Apparent Diffusion Coefficient (ADC) as a severity index of the leukoaraiosis regions. A significant correlation (p=0.015) was found between ADC and  $K_{BBB}$  (Fig. 2), suggesting a possible link between vascular damage and tissue structural integrity. Finally, we tested to see whether signs of tissue damage can already be observed in NAWM and, if so, which parameter is most sensitive to these early stage changes. We calculated correlation coefficient between the total areas of leukoaraiosis and each of the measured parameters in NAWM. Fig. 3 shows that CVR in NAWM is significantly correlated with leukoaraiosis volume (p=0.05), suggesting that CVR appears to be an early event and may precede the manifestation of lesion. No correlations were found between leukoaraiosis volume and CBF,  $K_{BBB}$ , ADC or FA in NAWM (p>0.21).

In summary, our data show that leukoaraiosis regions are characterized by vascular damages including reduced blood supply, reduced vascular reserve and significant leakage in BBB, suggesting a combined mechanism of tissue ischemia and serum protein toxicity. In addition, vascular reserve in NAWM was found to be indicative of extent of leukoaraiosis, suggesting that NAWM may also be at risk of imminent vascular damage.

**REFERENCES:** 1) Lammie et al. *Stroke*, 28:2222, 1997; 2) Wardlaw et al. *Stroke*, 34:806, 2003; 3) Akiguchi et al. *Acta Neuropathol.*, 95:78, 1998; 4) Wong et al. *Magn Reson Med.*, 58:1086, 2007; 5) Yezhuvath et al. *NMR Biomed.*, 22:779, 2009; 6) Lu et al. *Magn Reson Med.*, 54:1403, 2005; 7) Lu et al. *AJNR* 29:373, 2008; 8) Grubb et al. *Stroke*, 5:630, 1974; 9) O'Sullivan *Pract Neurol.*, 8:26, 2008.

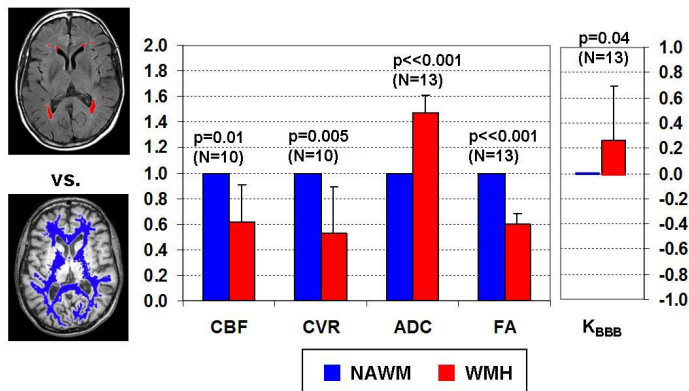


Fig. 1: Comparison of vascular and structural parameters between NAWM (blue) and WMH (red). The CBF, CVR, ADC, and FA values were normalized by NAWM.  $K_{BBB}$  of WMH is compared to that of NAWM which is zero by the definition.

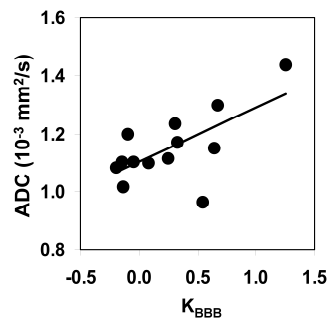


Fig. 2: Correlation between ADC and  $K_{BBB}$  in leukoaraiosis across individuals (r=0.66, p=0.015; N=13).

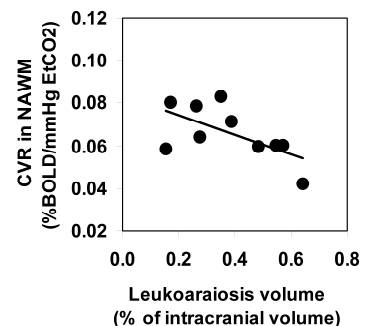


Fig. 3: Correlation between CVR in NAWM and the leukoaraiosis volume across individuals (r=0.63, p=0.05; N=10).