

## Variation in Signal Surrounding White Matter Lesions in Primary Progressive Multiple Sclerosis

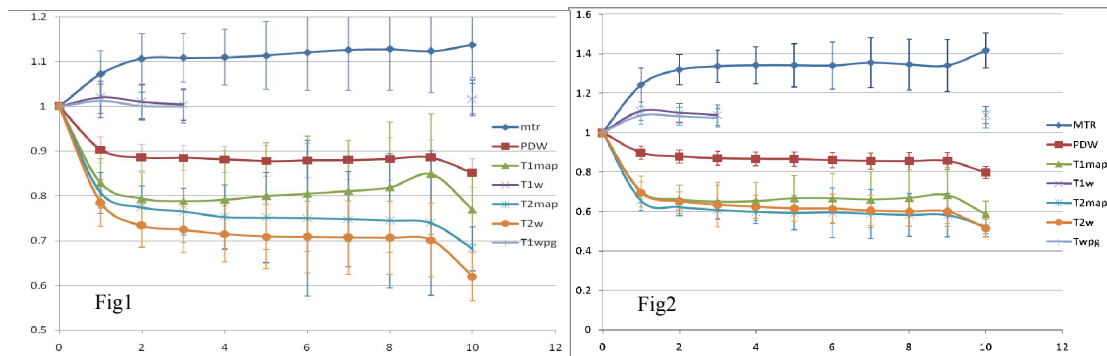
D. J. Tozer<sup>1</sup>, A. Hamid<sup>1</sup>, D. T. Chard<sup>1</sup>, D. H. Miller<sup>1</sup>, and A. J. Thompson<sup>2</sup>

<sup>1</sup>NMR Unit, Department of Neuroinflammation, UCL Institute of Neurology, London, United Kingdom, <sup>2</sup>Brain Repair and Rehabilitation, UCL Institute of Neurology, London, United Kingdom

**Introduction:** White matter (WM) lesions are the most visible multiple sclerosis (MS) pathology seen on MRI. However their correlation with disability is limited and many studies have shown abnormalities in the normal appearing WM of MS patients [1, 2]. However, most of these have involved histogram analysis and it is not clear if there is any spatial dependence related to these abnormalities. Vrenken et al. [3] have shown that the first few layers of pixels surrounding lesions on both T<sub>1</sub> and magnetisation transfer ratio (MTR) maps were abnormal compared to distant WM. This work investigates the region surrounding the lesion for a variety of MR parameters and contrasts and how the values obtained from the peri-lesional layers compare to the lesion and distant WM.

**Methods:** Fifteen patients with primary progressive MS (age: 27-57 years (mean = 45±9), 10 males, disease duration: 2-5 years (mean = 3), EDSS: 3-6.5 (mean = 4.7) were imaged on a 1.5 T Signa (GEMS, Milwaukee, WI, USA) with the following sequences (a 24x24 cm<sup>2</sup> field of view, a matrix size of 256x256 and coverage of 28 5 mm slices were used for all the sequences): 1) Dual echo FSE giving PD and T<sub>2</sub> weighted images: TR 2000ms; TE1/2 19/95 ms; Number of excitations (NEX) 1; Echo train length 8 (these images were also used to calculate a T<sub>2</sub> map based on a two point estimation); 2) T<sub>1</sub> weighted spin echo: TR 540 ms; TE 20 ms; NEX 1, both before and after the administration of gadolinium-DTPA as a contrast agent; 3) An interleaved dual echo spin echo sequence for MTR calculation: TR 1720 ms; TE1/2 30/80 ms; both echoes with and without an MT pulse; NEX 0.75; 4) Two gradient echo sequences used for T<sub>1</sub> map calculation i) TR 1500 ms; TE 11 ms; flip angle 45°; NEX 1; ii) TR 50 ms; TE 11 ms; flip angle 45°; NEX 1. These resulted in 7 image types which were used for analysis: PD, T<sub>1</sub> (pre- (T<sub>1</sub>W) and post- contrast (CET<sub>1</sub>)) and T<sub>2</sub> weighted images and quantitative T<sub>1</sub>, T<sub>2</sub> and MTR maps. All images were registered to the T<sub>2</sub> weighted images using a normalised mutual information cost function [4]. Forty eight lesions (a subset of the total lesion load) were marked on the T<sub>2</sub> weighted images that were at least 7-15mm from either the lateral ventricle or other CSF spaces. These lesions were isointense (10 lesions) or hypointense (38 lesions) on unenhanced T<sub>1</sub> weighted images. All lesions were 10-90mm<sup>2</sup> in area and showed no contrast enhancement. In addition 4 large regions were drawn in each patient away from the lesions in WM at different sites to provide a measure of the distant WM (dWM). A lesion mask was created and dilated up to 9 times, the dilated masks were combined with a WM segment obtained using SPM5 (www.fil.ion.ucl.ac.uk/spm/) and mean values extracted for the WM in each peri-lesional layer in turn. Mean values for each subject for each WM peri-lesional layer were compared with both the lesion and dWM using the Student's paired t-test and between the isointense and hypointense lesions using the unpaired t-test.

**Results:** Figures 1 (isointense) and 2 (hypointense) show the behaviour of the parameters and signal intensities moving away from the lesion. The y-axis values are normalised to the lesion value, which appears at 0 on the x-axis, 10 relates to the dWM.



Tables 1 (isointense) and 2 (hypointense) show the peri-lesional layers that are statistically different compared to the lesion and dWM and whether the lesion and dWM differ ( $p < 0.05$ ). Investigating the difference between the

isointense and hypointense lesions showed that all the layers in the MTR and T<sub>1</sub> map (except the 9th pixel layer in T<sub>1</sub> map) differ between the two types of lesions ( $p < 0.05$ ), while the other parameters showed no differences.

**Conclusions:** This work suggests that the peri-lesional tissue around T<sub>2</sub> weighted visible lesions is abnormal and that this abnormality varies from MR modality to MR modality and for the two lesion types. For example, the MTR in the isointense lesions is indistinguishable from distant WM from the 2<sup>nd</sup> layer onwards; however for the hypointense lesions all the layers are significantly different to both the lesion and dWM. The T<sub>1</sub> map shows some interesting results, for the isointense lesions, layers 1-6 rows not statistically distinguishable from the dWM, but layers 7-9 are significantly different from both the dWM and lesion. For the hypointense lesions a similar pattern is seen, but all the layers reach significance for differences from lesion and dWM. These differences may reflect different pathologies highlighted by the various parameters. The differences seen between the areas surrounding the isointense and hypointense lesions may well reflect the difference in ages between the two lesion types, in particular the differences in inflammation which may resolve in older hypointense lesions. Both the MTR and T<sub>1</sub> are known to vary with the amount of free water in a tissue so the differences could be explained in this manner. What is more surprising is that the abnormality seen 7-9 mm away from the lesion around the isointense lesions in the T<sub>1</sub> map, which suggests a pathology remote to the lesion and possibly independent of it, however with only a few lesions this result should not be considered proven.

**Acknowledgements:** This work was funded by the MS society of GB and NI, AH was funded by the MBI Aljibar foundation

**References:** [1] Barbosa et al. MRI 1994;12:33-42 [2] van Buchem et al. MRM 1996;36:632-636 [3] Vrenken et al. AJNR. 2006;27:2005-2011 [4] Studholme et al. Pattern Recognition. 1999;32:71-86

Table 1	Lesion	dWM	Table 2	Lesion	dWM
MTR	1-9, dWM	1	MTR	1-9, dWM	1-9
T <sub>1</sub> map	1-9, dWM	1, 7-9	T <sub>1</sub> map	1-9, dWM	1-9
T <sub>2</sub> map	1-9, dWM	1-8	T <sub>2</sub> map	1-9, dWM	1-9
T <sub>2</sub> W	1-9, dWM	1-9	T <sub>2</sub> W	1-9, dWM	1-9
PDW	1-9, dWM	1-9	PDW	1-9, dWM	1-9
T <sub>1</sub> W	-	-	T <sub>1</sub> W	1-3, dWM	1
CET <sub>1</sub>	-	-	CET <sub>1</sub>	1-3, dWM	1-3

The second column indicates the layers (and dWM) which are significantly different to the lesion. The third column gives this information for the dWM.