

# CORTICAL N-ACETYL ASPARTATE PREDICTS LONG-TERM CLINICAL DISABILITY IN MULTIPLE SCLEROSIS – A LONGITUDINAL MR SPECTROSCOPIC IMAGING STUDY

X. Wu<sup>1</sup>, L. G. Hanson<sup>1,2</sup>, M. Blinkenberg<sup>3</sup>, A. Skimminge<sup>1</sup>, P. S. Sørensen<sup>3</sup>, O. Paulson<sup>1,4</sup>, and H. Mathiesen<sup>1,3</sup>

<sup>1</sup>Danish Research Center for Magnetic Resonance, MR Dept., Copenhagen University Hospital Hvidovre, Hvidovre, Denmark,

<sup>2</sup>Department of Electrical Engineering, Technical University of Denmark, Denmark, <sup>3</sup>Danish MS Research Center, Neurology

Dept., Copenhagen University Hospital Rigshospitalet, Denmark, <sup>4</sup>Dept. Neurology and Neurobiology Research Unit, Copenhagen University Hospital Rigshospitalet, Denmark

## Introduction

Multiple sclerosis (MS) is an inflammatory demyelinating disease of the central nervous system, and cortical pathological changes have been recognized by histopathological examination. Magnetic resonance spectroscopic imaging (MRSI) provides *in vivo* tissue metabolic information about neuronal damage, loss, or dysfunction by measuring N-acetyl aspartate (NAA). NAA has been suggested as a marker of neurodegeneration and disease progression in MS. This longitudinal study was designed to observe the time course of NAA/Creatine (Cr) changes and further to test the hypothesis that cortical NAA/Cr is a predictor of neurological disability in early relapsing-remitting (RR)MS.

## Patients and methods

Sixteen patients with newly diagnosed RRMS were studied by serial MRI and MRSI once every 6 months for 24 months. Clinical examinations including the Expanded Disability Status Scale (EDSS) were performed at baseline, month 24, and again at year 7. A multi-slice echo-planar spectroscopic imaging (EPSI) sequence (1) was applied to MS patients in addition to conventional MRI on a Siemens Vision 1.5 T scanner. Eight 10 mm axial slices covered most of the cerebrum with 1 cm<sup>3</sup> isotropic voxels (Fig1). Cortical NAA were calculated as ratio relative to Cr to correct for cerebrospinal fluid (CSF) content, coil sensitivity variations, and edema. The FLAIR images were registered to the spectroscopic water reference images, and a border of approximately 1 cm was semi-automatically selected at surface of the brain based on the FLAIR images to provide information of cortical NAA/Cr changes (Fig 2), the small peak heights in the cortical spectrum result from significant CSF contamination.

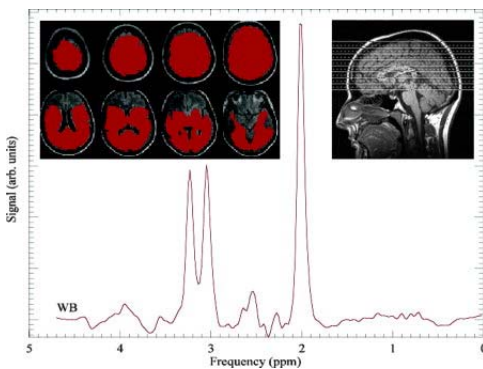


Fig 1. Spectrum and ROIs of this multi-slice EPSI

## Results

There were no significant changes in EDSS at month 24 compared to baseline. EDSS increased significantly at year 7 compared to baseline ( $p < 0.01$ ) or month 24 ( $p < 0.05$ ). There were fluctuations of cortical NAA/Cr during the 24 months follow-up, but it was not correlated with white matter lesion volumes or brain parenchymal fraction (BPF).

Baseline cortical NAA/Cr ratio was negatively correlated with EDSS at month 24 ( $r = -0.61$ ,  $p < 0.05$ ), it was also negatively correlated with EDSS at year 7 ( $r = -0.60$ ,  $p < 0.05$ ). Baseline BPF was negatively correlated with EDSS at month 24 ( $r = -0.62$ ,  $p < 0.05$ ), but not with EDSS at year 7. Neither the volume of T1 lesions nor the volume of T2 lesions was correlated with EDSS.

## Conclusion

This study indicates that cortical NAA/Cr is a prognostic marker of long-term clinical disability in early RRMS.

**Ref:** 1. Mathiesen HK, et al. Multi-slice echo-planar spectroscopic MR imaging provides both global and local metabolite measures in multiple sclerosis. *Magn Reson Med* 2005;53:750-759.

Fig 2. Brown represents cortical GM

