

A Five-Year Serial Longitudinal Study of Deep Gray Matter Atrophy in Patients with Multiple Sclerosis

R. Zivadinov¹, D. Horakova², M. G. Dwyer³, D. Ramasamy³, E. Havrdova², Z. Seidl⁴, O. Dolezal³, S. Hussein³, E. Carl³, M. Vaneckova⁴, and N. Bergsland³

¹Neurology, Buffalo Neuroimaging Analysis Center, Buffalo, NY, United States, ²Charles University, Department of Neurology, Prague, Czech Republic, ³University at Buffalo, Buffalo Neuroimaging Analysis Center, Buffalo, NY, United States, ⁴Charles University, Department of Radiology, Prague, Czech Republic

Objectives: To compare the evolution of deep gray matter (DGM) atrophy in early relapsing-remitting (RR) multiple sclerosis (MS) patients and in normal controls (NC) over 2 years. To investigate the extent of DGM atrophy progression in MS patients over 5 years.

Background: It has been shown that selective thalamic, caudate, hippocampal and caudate atrophy occurs early in RRMS. However, no longitudinal studies assessed the evolution of DGM atrophy over long-term in large cohort of MS patients.

Methods: We examined 180 early RRMS patients participating in the Avonex-Azathioprine-Steroid study (mean age 30.7 yrs, median disease duration 3.9 yrs and median EDSS 2.0) and 30 age- and sex-matched NC on a 1.5T scanner, using a high-resolution 3D-T1-SPGR sequence that was obtained on a yearly basis over 5 years (in NC only over first 2 years). Volumetric data for DGM structures (caudate, putamen, globus pallidus, thalamus, hippocampus, amygdala, nucleus accumbens) were obtained via automated parcellation of the images using the FSL FIRST software. Whole brain atrophy was measured by SIENA method as percentage brain volume change (PBVC). Regression analysis, adjusted for age and sex, was conducted to investigate the DGM volume evolution differences between NC and MS. Within-patient DGM volume changes were calculated over time. 3 MS patients and 3 normal controls were included in the reproducibility scan-rescan study.

Results: Scan-rescan was very similar across all regions and range between 0.5% and 5%. Less variability was observed for larger DGM structures. MS patients developed significantly more atrophy over 1 and 2 years in all DGM regions, compared to NC ($p < 0.001$). Over 5 years, significant DGM atrophy progression occurred in all examined DGM regions (all $p < 0.0001$). The DGM volume loss ranged between -4% and -10% according to the examined structure, and was the highest in nucleus accumbens, hippocampus, amygdala and thalamus. The PBVC loss was -4% over 5 years.

Conclusions: This serial yearly MRI study in early RRMS showed accelerated loss of DGM volume over 5 years. This suggests regional predilection of the pathologic process in MS.

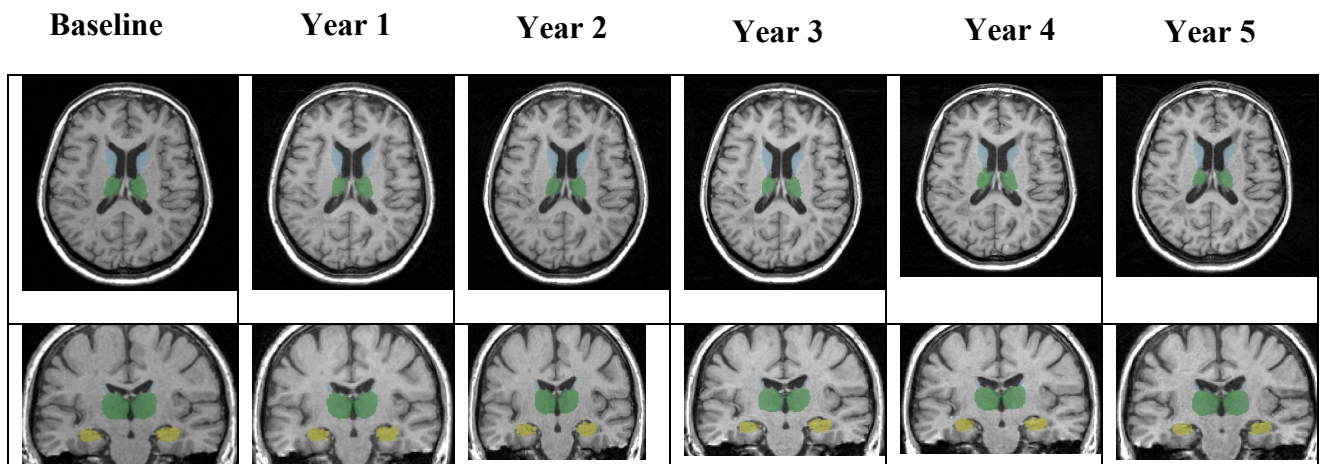


Figure. Deep gray matter volume (DGM) changes of representative relapsing-remitting multiple sclerosis patient on serial yearly 3D-T1-SPGR MRI scans over 5 years. The highest DGM volume decline occurred in the hippocampus (yellow color) and in the thalamus (green color). The baseline to year changes for various time points were noticed for hippocampus: year 1: -1.8%, year 2: -2.7%, year 3: -3.7%, year 4: -4.9%, year 5: -6.2%, whereas the changes for thalamus were, as follows: year 1: -1.6%, year 2: -2.6%, year 3: -3.5%, year 4: -5.1%, year 5: -6.1%. Substantial DGM volume decline was observed in other structures like caudate, putamen, nucleus accumbens and amygdala.