

Evidence of distributed subpial T2* signal changes at 7T in multiple sclerosis: an histogram based approach.

C. Mainero¹, C. Lima¹, J. Cohen-Adad¹, D. Greve¹, A. Radding¹, T. Benner¹, R. P. Kinkel², B. Fischl¹, and B. R. Rosen¹

¹A. A. Martinos Center for Biomedical Imaging, Massachusetts General Hospital, Charlestown, MA, United States, ²Neurology, Beth Israel Deaconess Medical Center, Boston, MA, United States

Introduction. Subpial lesions are the most frequent type of cortical lesion in multiple sclerosis (MS), and are thought to be closely associated with poor clinical outcome. Neuropathological studies report that subpial lesions may come in two major types: they may appear as circumscribed, focal lesions, or extend across multiple adjacent gyri leading to a phenomenon termed “general subpial demyelination” [1]. The *in vivo* evaluation of diffuse subpial disease is challenging – signal changes may be subtle, and extend across large regions where signal inhomogeneities due to B₁ and RF receive coil non-uniformities become more pronounced. Here, we investigate whether a histogram-based analysis of T₂* signal intensity in the cortex, at 7T MRI, can show evidence of distributed subpial cortical changes in patients with MS, as described histopathologically. We hypothesized that this phenomenon would be associated with significantly increased T₂* signal intensity in patients compared to age-matched controls.

Methods. Fourteen MS patients (nine with relapsing-remitting MS, RRMS; five with secondary progressive MS, SPMS; mean±SD age=38.9±12.9 years; median Expanded Disability Status Scale=3.0, range=1.0-6.5; mean±SD disease duration=10.2±7.7 years) and eight age-matched controls were scanned twice on a human 7T Siemens scanner using an in-house developed 8- or 32-channel phased array coil, and on a 3T Siemens Tim Trio scanner using the Siemens 32-channel coil. The 7T protocol included acquisition of 2D FLASH-T₂* spoiled gradient-echo weighted images (TR/TE=1000/22 ms, 20, 0.33×0.33×1mm³ slices). For each modality two to three slabs were acquired, allowing coverage of the supratentorial brain. A 3D MPRAGE (TR/TE/TI=2600/3.26/1100ms, 0.60×0.60×1.5 mm³ slices) with the same orientation as the FLASH-T₂* scans was also acquired. During the 3T session we acquired a high- structural 3D scan with a magnetization-prepared rapid acquisition with multiple gradient echoes (MEMPR) sequence resolution (0.9 x 0.9 x 0.9 mm³, TI=1200 ms, TR=2530 ms, flip angle=7°, TE=1.7+n.1.88 ms where n = 0, ..., 3, FoV=230 mm, bandwidth=651 Hz/px). Prior performing the histogram quantitative analysis of T₂* signal in the cortex, all 7T images were corrected for coil sensitivity profiles using a non-uniformity correction algorithm [2].

Pial and white matter (WM) surfaces generated by FreeSurfer on the 3T MEMPR (<http://surfer.nmr.mgh.harvard.edu>) were overlaid on the 7T FLASH-T₂* scans. Registration between FLASH-T₂* scans and the FreeSurfer anatomical reconstructed whole-brain 3T MEMPR was performed in several stages: 1) the whole-brain MPRAGE collected during the 7T session was registered to the FreeSurfer anatomical using the FSL FLIRT registration tool (www.fmrib.ox.ac.uk/fsl); 2) an initial registration between the partial FoV of the FLASH-T₂* slabs and the 7T MPRAGE was computed from the geometry information found in the DICOM header; 3) a registration between the FreeSurfer anatomical and FLASH-T₂* slabs was performed by concatenating these volumes to the 7T MPRAGE. Because this is only accurate if the subject does not move, the final registration was computed based on the actual intensity values. For this purpose a new registration procedure, Boundary-Based-Registration (BBR), was used [3]. FLASH-T₂* partial volumes were then combined into a 0.33×0.33×0.33 mm³ single volume in the anatomical space. In places where the partial volumes overlap, they were averaged together. T₂* intensities were normalized to the mean CSF intensity (T₂*/CSF) and then sampled 1mm inside the pial surface.

Histograms of T₂*/CSF intensity in the subpial cortical volume across the whole right or left hemisphere, or in selected cortical regions were normalized by the total number of voxels included to correct for between-participant variability in brain volumes. For each histogram the following metrics were derived: a) Relative Peak Height (RPH), which measures the percent of voxels at the most common T₂*/CSF value; b) Peak Position (PP), which measures the most common T₂*/CSF value; c) T₂*/CSF₂₅, T₂*/CSF₅₀, T₂*/CSF₇₅, which indicate the T₂*/CSF at which the respective integrals of the histograms are 25%, 50% and 75% of the total area under the curve; d) the Average of T₂*/CSF (Av T₂*/CSF) of the region analyzed. Histogram-derived metrics were compared between all patients, and in SPMS only vs controls using Student's t-test for unpaired data. For this preliminary study we focused our analysis in the whole right or left hemisphere and in different frontal regions including the frontal pole, superior frontal gyrus, rostral middle frontal gyrus, and cingulate as pathology data demonstrated that these areas are greatly affected by diffuse subpial demyelination.

Results. With the exception of RPH, all T₂*/CSF histogram-derived metrics for the whole cortex in the right hemisphere were greater in the group of all patients vs controls (PP= 38.7±5.7 vs 36.5±4.9; T₂*/CSF₂₅=33.8±5.5 vs 31.2±2; T₂*/CSF₅₀=39.4±5.2 vs 36.9±5.2; T₂*/CSF₇₅=44.7±4.5 vs 42.2; Av T₂*/CSF =0.64±0.1 vs 0.57±0.03) but only Av T₂*/CSF difference reached statistically significance (p<0.04). Similarly, Av T₂*/CSF in the left hemisphere was significantly higher in patients vs controls (0.63±0.1 vs 0.57±0.03, p<0.04). When we assessed T₂*/CSF histogram-derived metrics in frontal cortical regions, we found that the greatest increase in T₂*/CSF was in the right rostral middle frontal gyrus (Fig. 1, Table 1).

Fig. 1. Right Rostral Middle Frontal Gyrus

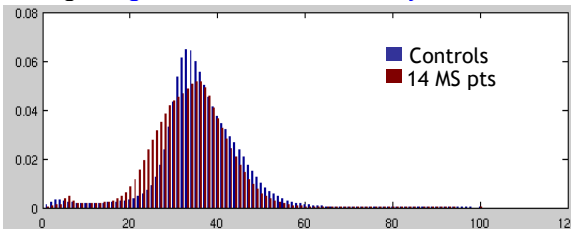


Table 1. T₂*/CSF histogram-derived metrics in the right rostral middle frontal gyrus

	Controls	14 MS patients	p-value
RPH (SD)	6.8 (1.4)	6.0 (1)	0.13
PP (SD)	40.5 (7.2)	41.6 (12.7)	0.8
T ₂ */CSF ₂₅ (SD)	36.7 (3.8)	40.9 (6.2)	0.07
T ₂ */CSF ₅₀	41.4 (5.2)	45.9 (6.1)	0.08
T ₂ */CSF ₇₅	45.7 (5.4)	51.1 (6.0)	0.04
Av T ₂ */CSF	0.6 (0.05)	0.7 (0.1)	0.04

Subpial T₂*/CSF changes were more evident in the subgroup of patients with SPMS, and involved mostly all the frontal regions analyzed in both hemispheres, though changes were greater in the right one. An example is shown in Fig. 2, Table 2.

Fig. 2. Right Cingulate

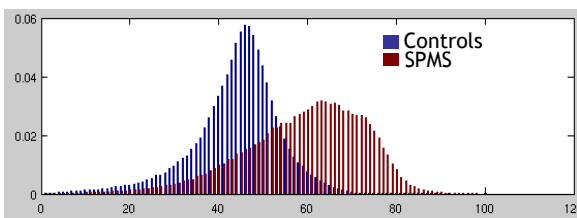


Table 2. T₂*/CSF histogram-derived metrics in the right cingulate

	Controls	SPMS	p-value
RPH (SD)	4.9 (0.8)	3.6 (0.7)	0.004
PP (SD)	62.1 (7.2)	70.20 (3.7)	0.01
T ₂ */CSF ₂₅ (SD)	53.0 (6.3)	55.4 (.7)	0.5
T ₂ */CSF ₅₀	60.7 (6.6)	65.6 (3.4)	0.09
T ₂ */CSF ₇₅	66.9 (6.5)	74.2 (2.3)	0.008
Av T ₂ */CSF	0.6 (0.04)	0.61 (0.05)	0.4

Conclusions. The histogram-based analysis showed significant, diffuse T₂*/CSF signal increases in MS patients vs matched controls, particularly evident in frontal areas and in SPMS. The observed changes may underlie diffuse subpial demyelination reported by several neuropathology examinations. This hypothesis can be validated by correlating histological evidence of diffuse cortical demyelination to the presence of diffuse cortical MR changes in ex vivo MS samples

References. 1. Stadelmann C. *Curr Opin Neurol* 21:229-34 (2008). 2. Sled, JG. *IEEE Trans Med Imaging* 17:87-97 (1998). 3. Greve D, Fischl. *Neuroimage* 48:3-72 (2009).

Acknowledgments. This study was partially supported by NIH (5P41 RR14075 08) and NMSS (4281-RG-A-1).