

# T1 and T2 relaxation time histograms of mandibular bone marrow: a monomodal distribution in sickle cell disease

J. Liao<sup>1</sup>, N. Nowrouzi<sup>1</sup>, E. Elias<sup>1</sup>, H. Jara<sup>1</sup>, and O. Sakai<sup>1</sup>

<sup>1</sup>Boston Medical Center, Boston University School of Medicine, Boston, MA, United States

**Introduction:** The deleterious effects of sickle cell disease (SCD) on bone tissue include osteomyelitis, marrow hyperplasia, and growth defects (Ref 1). SCD is also known to lead to the persistence of appendicular red marrow throughout life due to an increased demand for hematopoiesis; healthy adults, on the other hand, maintain red marrow only in the axial skeleton, with the rest of the body marrow space predominantly filled with yellow marrow (Ref. 2). Thus, the proportion of red to yellow marrow is altered in SCD patients. In previous studies, quantitative MRI (qMRI) has been used to delineate the relaxometry characteristics of red and yellow marrow in healthy subjects; yellow (fatty) marrow exhibits a short T1 relaxation time and a relatively long T2 relaxation time (Ref. 3, 4). However, these techniques have not yet been applied to the study of SCD, and can potentially yield insight to the extent of red marrow persistence in SCD patients.

**Purpose:** The purpose of this study is to identify and characterize SCD-related changes in the composition of mandibular bone marrow *in vivo* using established qMRI relaxometry techniques.

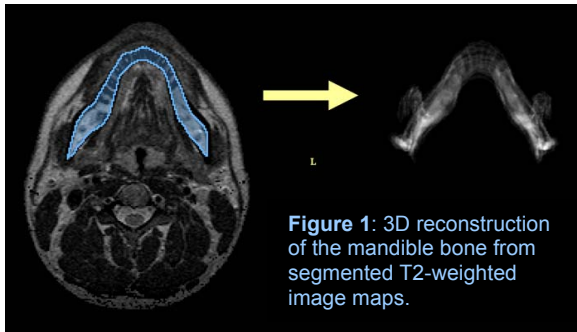


Figure 1: 3D reconstruction of the mandible bone from segmented T2-weighted image maps.

**Materials and Methods:** 13 SCD patients (19.8-43 years old, mean age 28.9 years old) and 17 age-matched controls (23-64 years old, mean age 37.7 years old) were imaged with the mixed turbo spin-echo pulse sequence at 1.5T (Ref. 5). As shown in Figure 1, the mandible was segmented manually at a 3 mm slice thickness using 3D Slicer, an open source software package for visualization and image computing (<http://www.slicer.org>). qMRI algorithms for 3D reconstruction and relaxation time histograms were written in MathCAD 2001i (PTC, Needham, MA). T1 and T2 histogram curves of each mandible were modeled with Gaussian functions, and peak values were plotted as a function of age. Bone volumes were calculated by virtual segmental volumetry in MathCAD2001i.

**Results:** The T1 and T2 histograms for every subject were shown to be either monomodal or bimodal. 15 of the 17 control subjects exhibited bimodal T1 histograms (mean T1 peaks = 404.49 ± 33.12 ms and 679.01 ± 54.45 ms); all 17 controls exhibited bimodal T2 histograms (mean T2 peaks = 64.84 ± 3.52 ms and 131.93 ± 10.79 ms) (Fig. 2a). In contrast, all 13 SCD patients exhibited monomodal T1 and T2 histograms (mean T1 peak = 790.49 ± 68.75 ms; mean T2 peak = 81.83 ± 12.88 ms) (Fig. 2b). The monomodal histograms seen in all SCD patients tended toward the longer peak in T1 and the shorter peak in T2, consistent with the non-fatty marrow (Fig. 3). There were no significant volumetric differences between the two groups.

**Conclusion:** T1 and T2 qMRI histograms of mandibular bone marrow in SCD patients are distinctively unimodal and this single histogram feature is identified with hematopoietic red marrow. To the best of our knowledge, this is the first qMRI report of hematopoietic marrow conversion in the mandible in the context of sickle cell disease.

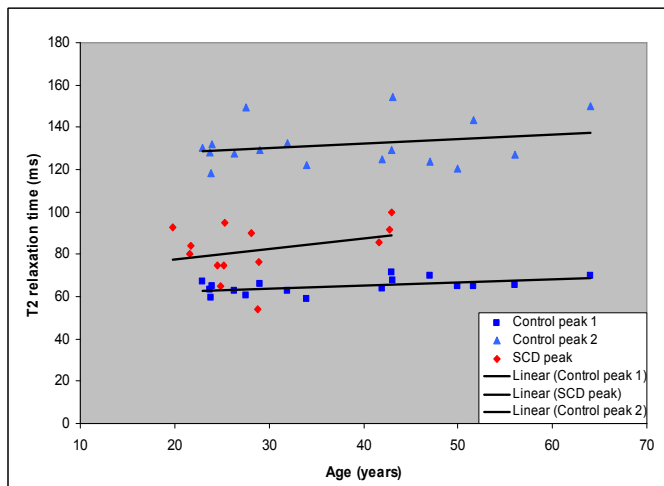
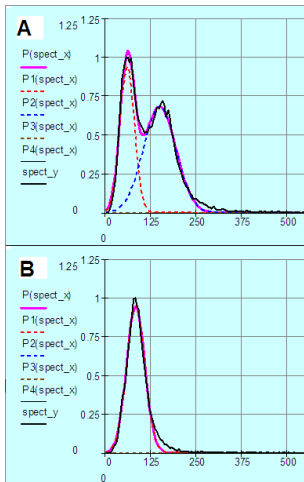


Figure 2a (left, upper): A T2 histogram of the mandible in a 28 year-old male without SCD. The abscissa shows MR relaxation time in milliseconds. A bimodal distribution is observed, with red and blue dotted lines representing curve-fitting algorithms written in MathCAD. 2b (left, lower): A T2 histogram of the mandible in a 22 year-old female with SCD. The resulting curve is monomodal and is similar in morphology to the shorter peak shown in (2a).

Figure 3 (right): T2 peak values of mandibular histograms plotted as a function of age. Monomodal peaks in SCD patients (red) correspond more closely to the shorter peaks in normal subjects (dark blue), showing no overlap with the longer peaks (light blue) which presumably represent the yellow marrow compartment. There is no strong age-related correlation in peak values.

## References:

1. Ejindu VC, Hine AL, Mashayekhi M, Shorvon PJ, Misra RR. **Musculoskeletal manifestations of sickle cell disease.** RadioGraphics 2007; 27:1005-1021.
2. Vogler JB, Murphy WA. **Bone marrow imaging.** Radiology 1988;168:679-693.
3. Vande Berg BC, Malghem J, Lecouvet FE, Maldague B. **Magnetic resonance imaging of the normal bone marrow.** Skeletal Radiol (1998) 27:471-483
4. Mouloupoulos LA, Dimopoulos MA. **Magnetic resonance imaging of the bone marrow in hematologic malignancies.** Blood (1997) 90(6): 2127-2147.
5. Saito N, Sakai O, Ozonoff A, Jara H. **Relaxo-volumetric multispectral quantitative magnetic resonance imaging of the brain over the human lifespan: global and regional aging patterns.** Magn Reson Imaging 2009; 27(7):895-906.